

A Comparison of Canine and Avian Skeletal and Respiratory Systems and Diseases

Honors Thesis

Presented in Partial Fulfillment of the Requirements for the University Honors Program

Colorado State University

By

Autumn Ryann

Department of Zoology

Jason Martin, DVM, PhD, Department of Biomedical Sciences

Paulina Svec, MS, Department of Biomedical Sciences

Fall 2025

## **A Comparison of Canine and Avian Skeletal and Respiratory Systems and Diseases**

### **Abstract**

Utilizing comparative anatomy, we aim to expand anatomical knowledge of canine and avian species in those with basic understanding of the skeletal and respiratory systems. The canine is utilized as a model for comparison to establish general anatomical principles before introducing the evolutionary adaptations of the avian skeletal and respiratory systems, supporting the idea that form follows function. Additionally, variations in anatomy create a divergence in presentation, diagnosis, and treatment of various pathologies of these systems. The canine skeletal system is largely unfused, with many joints and flexibility, allowing efficient terrestrial locomotion and maneuverability. The avian skeletal system has many aspects of fusions in the vertebrae and appendages, providing rigidity that assist in flight stability and lowering mass. Canine respiration is bidirectional, requiring one inhale and one exhale for a full respiratory cycle. Avian respiration is unidirectional, requiring two inhales and two exhales for a full respiratory cycle, maximizing gas exchange for flight at altitudes with lower oxygen levels. Fractures cause problems in the skeletons' structural integrity no matter the species. Canine rib fractures can be deadly, decreasing respiratory efficiency and increasing risk for secondary infections. Avian fractures impact the respiratory system in pneumatic bones, which often contain air sacs. Rupture of air sacs through fractures can increase risk of respiratory and bone infections, and often require surgical intervention. A fungal infection like aspergillosis primarily affects avian species, though it can present as sinonasal aspergillosis or disseminated aspergillosis in canines. Avian influenza (AI) affects both avians and canines, and can present as low or high pathogenicity in avian species. Generally, canines infected with AI have mild symptoms, though it can mutate in canines and establish a lineage of canine influenza.

## Contents

<b>Introduction.....</b>	<b>4</b>
<b>The Skeletal System.....</b>	<b>4</b>
Bone Microanatomy.....	5
The Skull.....	6
Canine & Avian Overview.....	6
The Orbit.....	8
Kinesis.....	8
Pneumatics.....	10
Spinal Articulation.....	11
The Vertebral Column.....	12
Vertebral Structure.....	12
Movement Assisted by Flexibility or Rigidity.....	14
The Ribcage and Sternebrae.....	15
Ribs.....	15
Sternebrae.....	16
Clavicle & Shoulder Girdle.....	18
The Pelvic Limbs.....	20
Flow of Bones.....	20
Limb Function.....	23
The Thoracic Limb.....	24

	4
Flow of Bones.....	24
Limb Function.....	26
<b>The Respiratory System.....</b>	<b>28</b>
Structures of Respiration.....	28
Canine Respiration.....	28
Avian Respiration.....	29
Mechanisms of Ventilation.....	32
Canine Ventilation.....	32
Avian Ventilation.....	33
<b>Pathologies.....</b>	<b>34</b>
Skeletal Injuries.....	35
Types of Fractures.....	35
Fractures in Canines.....	36
Fractures in Avians.....	37
Respiratory Diseases.....	39
Aspergillosis Infection.....	39
Avian Influenza Infection.....	42
<b>Conclusion.....</b>	<b>44</b>
<b>References.....</b>	<b>45</b>

## **Introduction**

Dogs and birds are two of the most common animals humans interact with. These interactions are in different contexts, with dogs being the most commonly owned pet in America, and birds being the most common wildlife humans interact with (AVMA, 2024; Hummel et al., 2015). Despite the common interactions we have with these two animals, there is a large gap in common knowledge of anatomy of dogs versus birds. Utilizing and building on basic knowledge of canines, avian anatomy can be shared in a way that is easier to digest. Often, having simple knowledge of one species can make learning about the variations of another species easier, comparing and contrasting similarities and differences.

Beginning with the skeletal systems of each species, a foundation of knowledge is built on the evolutionary modifications for avian flight. The skeleton of each animal will be broken down section by section, introducing canine structures before avian modifications. The introduction of the canine respiratory system allows for a basic understanding of gas exchange before describing the complex avian respiratory system and its modifications for flight. As the variations in each system are discussed, we emphasize that form follows function in both the terrestrial canine and the aerial avian. Following this idea into clinical relevance, fractures bridge the gap between skeletal and respiratory systems in the form of flail chest and in pneumatic bones. Respiratory illnesses emphasize how anatomical differences present the same infection in different ways, both in fungal and in viral cases.

## **The Skeletal System**

The skeletal system is made of various shapes and sizes of bones to protect organs, assist in movement, and provide overall structure to the body. First, knowing the general set-up of canine and avian skeletons, along with bone composition, will allow stronger understanding of

structures, modifications, and pathologies in both species. In canines, the axial skeleton is composed of the skull, vertebrae, and ribs. The appendicular skeleton consists of the thoracic limbs and the pelvic limbs. Both thoracic and pelvic limbs in canines are weight bearing, as they are quadrupedal animals, and walk on all fours. The avian axial skeleton is also composed of the skull, vertebrae, and ribs, with several modified areas of fusion. The avian appendicular skeleton maintains thoracic and pelvic limbs, though only the pelvic limbs are weight bearing. Avians are bipedal animals, with wings as modified thoracic limbs. To assist in the function of flight and stability in landings, there are changes in bone macro and microstructure along with several fusions within the skeleton. The largest modification that allows for flight is the keel bone. The keel is the modified avian sternum with expanded surface area, allowing for the attachment of strong flight muscles (Dyce, 2009).

**Figure 1**

Image of a Chicken Skeleton



*Note.* Fully articulated chicken skeleton. Author's photograph.

## **Bone Microanatomy**

Looking at the structure of bone as a tissue, there are two primary types: compact and spongy (Gonzalez, 2019). Compact bone may be referred to as cortical bone, while spongy bone may be referred to as cancellous or trabecular bone. Compact bone tissue can be found forming the outer layer of bone, as well as forming both the outer and inner layers of the neurocranium (the aspect that holds the brain) within the skull. This type of bone is dense, but has canals for neurovascular structures. Spongy bone is often found internally in ribs, vertebrae, short or flat bones, and in the ends (epiphysis) of long bones. It is made up of an irregular webbing pattern of bone, with spaces filled in by bone marrow. The central part of long bones (diaphysis) has an internal medullary cavity that is also filled in by bone marrow. In long bones, the central “long” part is called the diaphysis. Within the diaphysis, there is a medullary cavity filled with bone marrow (Gonzalez, 2019). Bone marrow is a tissue that assists in the production of blood cells and cells of the lymphatic system (Travlos, 2006).

In female avian species, the compact bone is replaced with medullary bone at sexual maturity, which is less dense, but higher in calcium content. As these female birds begin to form eggs, the calcium from medullary bone is utilized to form eggshells (Alfonso-Carrillo et al., 2021). Additionally, many avian bones are pneumatic (air filled cavity within the bone), highly reducing the amount of spongy bone in the humerus, the femur, and flat bones like the skull, vertebrae, and pelvis (Burton et al., 2023; Gonzalez, 2019). Pneumatic bones are not unique to avian species. Mammals have pneumaticity in the skull via paranasal sinuses, which are extensions of the nasal cavity. These sinuses are impacted by respiratory diseases, such as aspergillosis, but do not have air sacs within them like most pneumatic bones found in avian species (Mortellaro, 2002). Postcranial skeletal pneumaticity, or PSP, is when there are

pneumatic bones of the skeleton other than the skull. PSP is a feature unique to avians, and can often be attributed to air sacs extending into the bones. The air sacs are ventilators or bellows for the non-expansile avian lung, facilitating the movement and flow of air, and are located throughout the body (Burton et al., 1995).

## **The Skull**

### ***Canine & Avian Overview***

The skull will be described in segments, beginning with the canine structures before describing modifications to those structures in the avian skeleton. The canine skull has major variation across breeds due to the breeding for or against certain characteristics as they relate to breed function (Georgevsky et al., 2014). The variations in skull shape have been defined by the cephalic index, which is the ratio of skull width to length. One of three classifications are given based on this ratio: dolichocephalic (such as an Italian greyhound), mesocephalic (such as a Golden Retriever), or brachycephalic (such as a French bulldog), as seen in Figure 2 (Bognar et al., 2021).

**Figure 2**

*Skull Shape Variations in Dog Breeds*



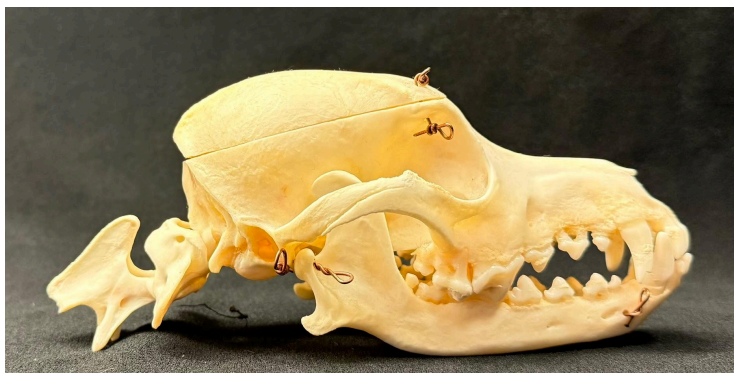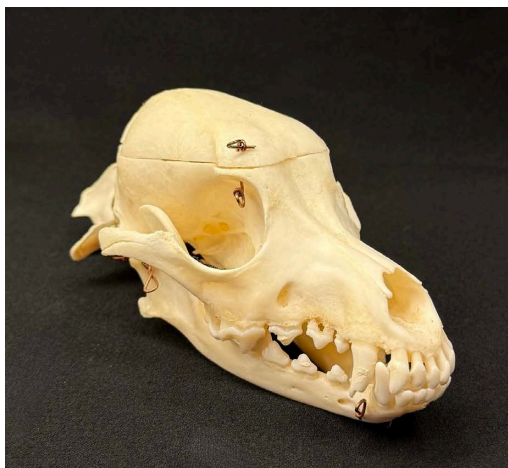*Note.* A- Dolichocephalic breed, B- Mesocephalic breed, C- Brachycephalic breed. Image obtained from Dyce, 2009, p. 375.

These skull shapes may predispose certain breeds to particular diseases, such as breathing problems in brachycephalic dogs, or aspergillosis in dolichocephalic breeds (Liu et al., 2017; Tell

et al., 2019). In shape, the skull is generally longer than it is wide, with the caudal (towards the tail) half being the bones that make up the braincase (cranial bones) and the rostral (towards the nose) half being bones that make up the face and jaw (facial bones), as seen in Figure 3. The cranial bones act to protect the brain, while facial bones provide attachment points for the muscles of mastication (chewing) (Dyce, 2009)

### Figure 3

Images of Canine Skull

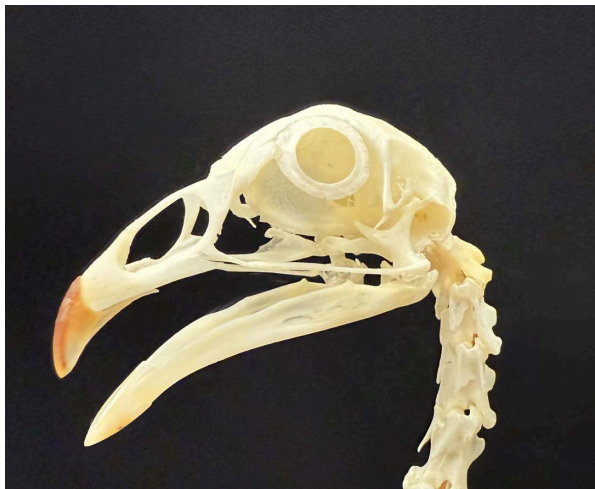

*Note.* The top image displays a more rostral view, while the bottom image displays a lateral view. This skull also has the atlas (first cervical vertebrae) and the axis (second cervical vertebrae). Author's photograph.

Avians as a category span songbirds, domesticated birds, waterfowl, raptors, and more, allowing for a wide range of variation in modifications and attachments across many species. Generally, skull structure remains the same, with some modifications and species variations. There are aspects of fusion, additional movements, and functional aspects. The shape bears similarities to a canine skull, with cranial bones protecting the brain caudally and facial bones for muscle attachment rostrally, as seen in Figure 4.

#### **Figure 4**

Image of Avian Skull



*Note.* Chicken skull with a lowered mandible, displaying skull structure and scleral rings. Author's photograph.

#### ***The Orbit***

In the canine skull, the orbit, where the eye is located, is not fully enclosed by bone. The orbital ligament completes the orbit, ultimately forming a funnel shaped area for the oblate spherical eyeball to sit (Chiwitt, et al., 2017; Dyce, 2009). The incomplete orbit can be seen in Figure 3.

In addition to orbital bones and ligaments, the avian skull includes scleral ossicles, which are bony rings around the cornea of the eye, which are visible in Figure 4. The avian eye is generally tubular, though the eye shape and size varies depending on their activity patterns. Nocturnal birds (active at night), tend to have larger corneas and longer eyes when compared to diurnal birds (active during the day) (Hall & Ross, 2006). The eye partially protrudes from the orbit, due to the shape, and the sclerotic rings (scleral ossicles) provide structural support and protection from trauma to this portion of the eye. Additionally, along with assisting in visual accommodation, or ability to change focus on near or distant objects. Good visual precision and acuity is crucial for flight, hunting, and survival (Hall, 2008; Masoudifard et al., 2025). The heightened eyesight of avian species is critical in nocturnal and crepuscular (active at dawn and dusk) birds, along with those that hunt smaller prey animals. Canines are diurnal and do not rely on hunting for survival, decreasing their need for amplified eyesight.

### ***Kinesis***

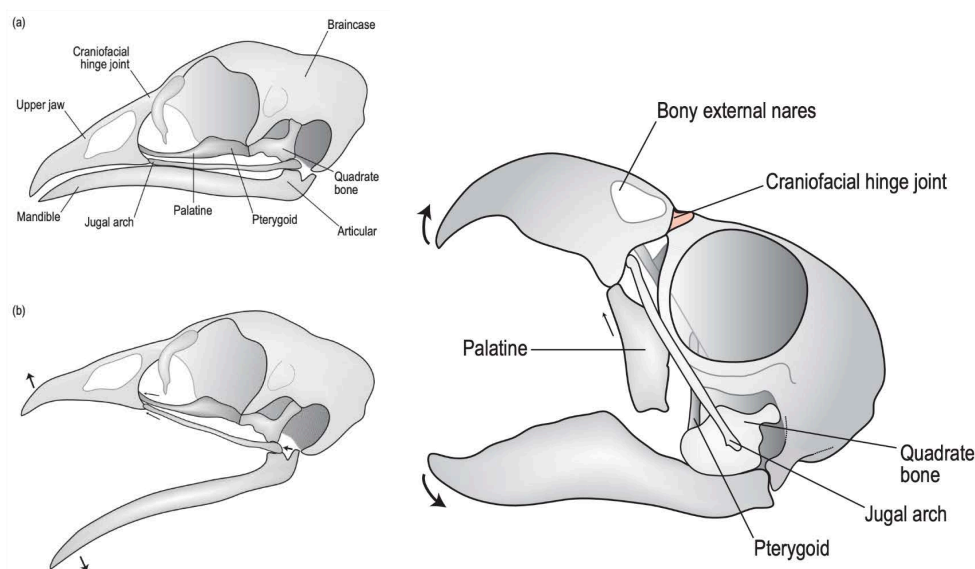
In canines, the temporomandibular joint (TMJ) is where the mandible, or lower jaw, articulates with the temporal bones of the skull. The mandible is composed of a left and right aspect that articulate together rostrally. Caudally, the left and right mandibles articulate with the left and right temporal bone, forming the left and right temporomandibular joints. This joint can be seen in the lateral view of Figure 3. The TMJ is responsible for movement of the skull, utilized in mastication and bite force, and is the only major joint of the canine skull. This structure makes the canine skull akinetic, or static, as the TMJ is the only area of movement (Dyce, 2009; Wilken, et al., 2019).

The mandibular attachment to the skull differs in avians, with the mandible directly articulating with the articular and quadrate bones. These bones have similar evolutionary origin

to the middle ear bones present in mammals. In avian species these bones are located laterally on the ventral caudal aspect of the skull (Anthwal et al., 2012; Dyce, 2009). Ventral structures are those located toward the sternum or belly, while dorsal structures are toward the spine or back. Additionally, the mandible is one bone, rather than the left and right aspects in canines. The rostral aspect is fused, opposed to articulation in canines. The joint formed between the articular, quadrate, and mandibular bones allows typical up and down movement of the mandible, as seen in canines. However, in birds, depression or lowering of the mandible will rotate the quadrate bone, pushing the maxilla (upper jaw) rostrally. This rotation can be visualized in Figure 5.

**Figure 5**

Diagram Displaying Kinesis Within Avian Skulls



*Note.* Left diagram displaying kinesis within a chicken skull. Right diagram displaying kinesis within a parrot. Diagram obtained from O'Malley, 2005, p. 102.

Ultimately, the movement of kinetic skulls is a spectrum with some avian species demonstrating more drastic kinesis than others. This ability for movement assists in feeding functions, such as manipulating food before ingestion, as well as in climbing scenarios. In parrots, the beak is

utilized to form a tripod gait when climbing, assisting in grip and propulsion (Young et al., 2023). Canines utilize their jaws for chewing and strong bite forces, which are enabled in a static skull. With no need for mastication, avian skulls are more adapted to their lifestyle with kinesis for movement assistance and food manipulation such as ripping and tearing.

### ***Pneumatics***

As previously mentioned, the canine skull is pneumatized, particularly in the paranasal sinuses. These sinuses are outpouches (diverticula) of the nasal cavities that hollow out the facial bones of the skull. The pathway between nasal cavity and paranasal sinus is small, meaning the exchange of air between the two structures is quite slow. While pneumatic and part of the upper respiratory tract, they have no direct connection to respiratory structures other than the nasal cavities (Dyce, 2009; Keir, 2009).

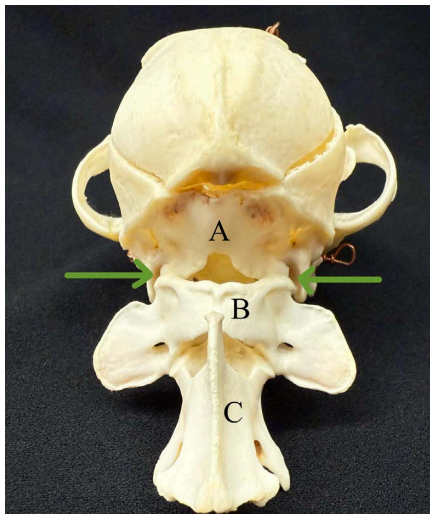
Avian species have extensively pneumatized skulls, primarily to minimize weight to assist in the ease of flight. The pneumatic area of the avian skull is the infraorbital sinus, which is similar to the paranasal sinuses of the canine in that it is partially composed of a diverticula of the nasal cavity. There are many pathways and diverticula in the infraorbital sinus and nasal cavities, forming a complicated system that makes respiratory infection particularly dangerous (Gartrell et al., 2011). The pneumaticity in the avian skull can also be attributed to the extension of the cervicocephalic air sac, further decreasing the weight of the skull (Maina, 2022). Simple pneumatization in the canine skull aligns with the relatively simple canine respiratory system. In avians, the decrease of body mass and complexity of the avian respiratory system is reflected in the extensive pneumatic pathways in the avian skull.

### *Spinal Articulation*

The caudal portion of the canine skull articulates with the first vertebrae, called the atlas. In canines, this articulation is formed between the occipital bone, which has two condyles that fit snugly into the atlas. This junction is named the atlantooccipital joint, after the two bones of the joint. The occipital bone is also home to the foramen magnum, which is where the brainstem passes out of the skull and into the vertebral column and becomes the spinal cord (Dyce, 2009).

#### **Figure 6**

Image of Canine Atlantooccipital Joint



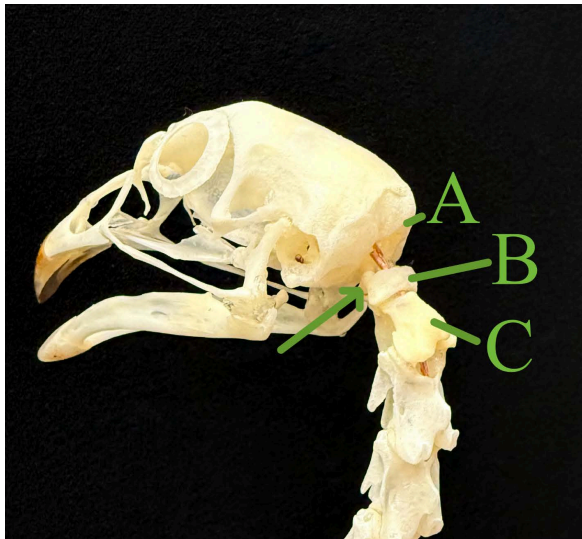
*Note.* Caudal portion of a canine skull, with arrows pointing to the atlantooccipital joint. A- Occipital bone of the skull, B- Atlas (first cervical vertebrae), C- Axis (second cervical vertebrae). Author's photograph.

In avians, the condyle of the occipital bone articulates with the first vertebrae, still called the atlas in avian species. However, there is only one condyle forming this attachment. This singular attachment assists in the ability to rotate the head to higher degrees than in animals with two occipital condyles (Dyce, 2009). The avian foramen magnum is also located on the occipital bone, though there are variations across species in the positioning of the foramen. In some

species, such as eagles, falcons, owls, and parrots, the foramen magnum is located more ventrally, or toward the lower mandible. While in other species, such as pelicans, penguins, and cormorants, the foramen magnum is located more caudally, or centered in the back of the skull (Marugan-Lobon et al., 2021).

### Figure 7

Image of Chicken Atlantooccipital Joint



*Note.* The avian atlantooccipital joint is displayed in this image. A- Occipital bone of the skull, B- Atlas (first cervical vertebrae), C- Axis (second cervical vertebrae). Arrow points to the singular occipital condyle. Author's Photograph.

## The Vertebral Column

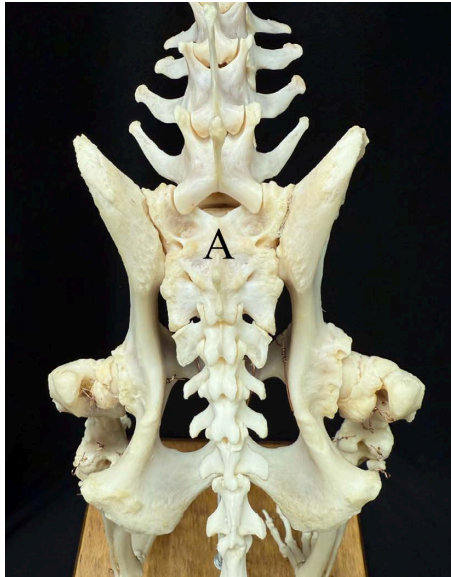
### *Vertebral Structure*

Moving past the skull, the vertebral column protects the spinal cord as it moves caudally and provides a large structural support for the body. There are five sections of vertebrae: cervical (of the neck), thoracic (of the thorax, which is bordered by the rib cage), lumbar (of the abdomen), sacral (of the pelvis), and caudal (of the tail). In canines, the typical formula for vertebrae is 7 cervical, 13 thoracic, 7 lumbar (sometimes reduced to 6), 3 sacral, and varying

caudal vertebrae depending on tail length. The three sacral vertebrae are fused into a structure called the sacrum, which is visible in Figure 8. The sacrum that lies within the pelvis is the only point of fusion within the canine vertebral column (Dyce, 2009).

### Figure 8

Image of Canine Sacrum



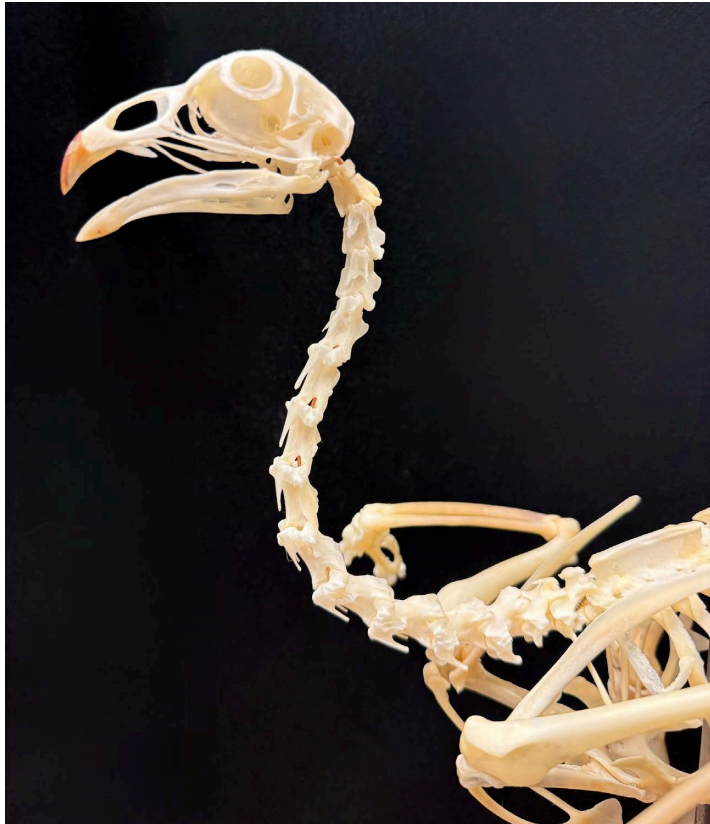*Note.* Aerial view of the canine pelvis. A- Fused sacrum. The head is toward the top of the image, while the tail is toward the bottom of the image. Author's photograph.

The avian vertebral column follows the same pattern, however, the number of each vertebrae varies by species and there are many aspects of fusion. Across species, the number of cervical vertebrae can range from 8 to 25. However, in chickens, there are 14 to 17 cervical vertebrae, with 14 seen in Figure 9. This large number of cervical vertebrae allows movement within the avian neck that is independent of the body. Independent movement of the neck allows for easier prey/food manipulation, ability to preen (groom) feathers, and even vertical climbing. Parrots pair kinetic skulls with elongated necks and extensive musculature to adapt tripedal movement for vertical climbing (Dyce, 2009; Marek, 2023). Movement within the avian neck

makes up for flexibility that is lost in the rest of the vertebral column, maintaining the ability to fully evaluate their surroundings without moving their entire body. In canines, this flexibility is present throughout the vertebrae, as they have no need for a rigid vertebral column.

### Figure 9

Image of Chicken Cervical Vertebrae



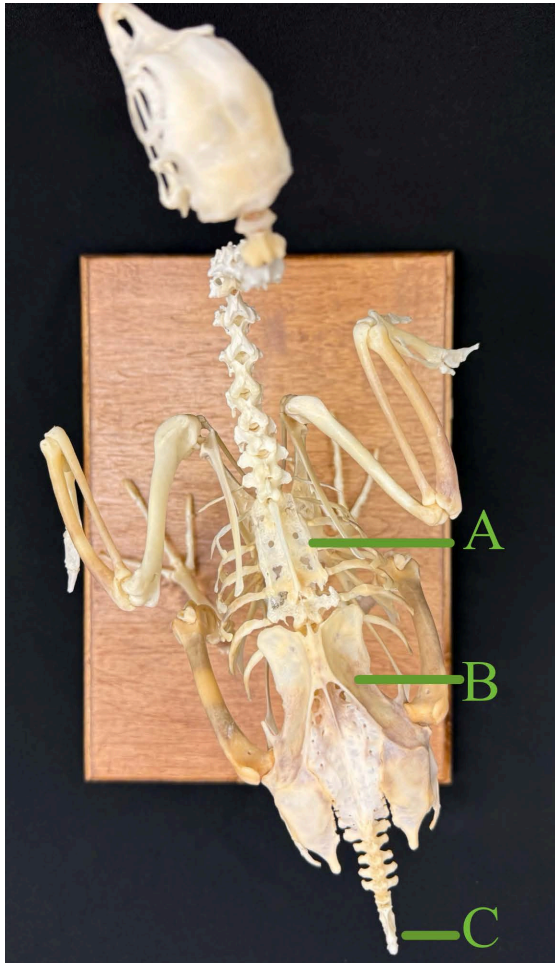
*Note.* This chicken specimen has 14 cervical vertebrae. Author's photograph.

There are no fusions in the cervical vertebrae, however there are fusions in the thoracic, lumbar, sacral, and caudal vertebral regions that are visible in Figure 10. These large areas of fusion assist in stabilizing flight, while providing strong structures for muscle attachment. In chickens, there are 7 thoracic vertebrae. In other birds the thoracic region can range from 7 to 12 vertebrae, however, there is often an aspect of fusion between these vertebrae. The fused

structure of the thoracic vertebrae is called the notarium, and can contain anywhere from 2 to 6 thoracic vertebrae.

**Figure 10**

Aerial Image of Chicken Skeleton



*Note.* This aerial view of the chicken skeleton displays aspects of fusion within the vertebral column. A- Notarium, B- Synsacrum, C- Pygostyle. Author's photograph.

Some species lack a true notarium, which requires at least one free (unfused) vertebrae between the thoracic and lumbar/sacral regions of fusion. Notably, the species lacking true notariums are fully terrestrial birds such as ostriches (Kassem et al., 2024; & Aries et al., 2021). Caudal to the thoracic vertebrae, there is a large pelvic structure called the synsacrum. The synsacrum is

composed of the most caudal 1 to 2 thoracic vertebrae, all lumbar, all sacral, and the first caudal vertebrae, along with the bones of the pelvis (Bui & Larsson, 2021; Dyce, 2009). The caudal vertebrae form the tail, which also has an element of fusion in birds. Within this region, the first caudal vertebra is fused to the synsacrum, followed by several free vertebrae, and ending with the pygostyle. The pygostyle is the fusion of the last 3 to 4 caudal vertebrae, forming a support structure for the tail. The total number of caudal vertebrae depends on the species and the length of each individual's tail, also dictating the number of free vertebrae (Felice, 2014).

### ***Movement Assisted by Flexibility or Rigidity***

The vertebral column acts to protect the spinal cord, forming structural and postural support within the trunk of the body. As animals move, the spinal column maintains the body structure while optimizing efficiency of movement (Dyce, 2009).

Canines are terrestrial quadrupeds that travel by walking and running. With each vertebrae (aside from the sacrum) remaining unfused and flexible, the canine spine can move and shift with each aspect of a given gait. In the trot of a healthy German Shepherd, the fluidity of movement in the hindlimbs and pelvis can be shifted into the spine and assist with propulsion. In fact, motion in the lumbar region of the spine primarily originates from the pelvis. Despite sharing the same motion pattern, different dogs, breeds, and strides have variation in pelvic and vertebral movement (Schaub et al., 2021).

Avians are bipedal animals that occupy terrestrial, aerial, arboreal, and aquatic spaces. Due to their wide range of habitats and ability to fly, walk, and swim, skeletal structures are modified across species. Fusions as a whole increase rigidity, which overall decrease the likelihood for dislocations during jarring movements, such as landing after flight (Bui & Larsson, 2021). The notarium provides a rigid structure that assists in the take-off section of

flight. When transitioning between being grounded and in flight, birds must have a strong structure that can absorb the shock of strong wing beats. There are hypotheses that the notarium provides structure to the respiratory system and the extensive neck musculature (Aires et al., 2021). The synsacrum provides axial support and acts as a shock absorber during the, often intense, landing section of flight (Bui & Larsson, 2021). This structure is large and extends ventrally which has sparked hypotheses of utility and support for the posture and bipedal nature of avian species (Dyce, 2009). Lastly, the pygostyle of the caudal vertebrae is an attachment point for tail feathers and musculature, which are crucial in directing flight and balance. Without a strong structure to support the tail feathers, flight, perching, and balance are impacted. Additionally, woodpeckers utilize their tail similar to the parrots use of their head and neck. When vertically climbing, the tail is utilized as a prop for stabilization (Felice, 2014). As canines only occupy terrestrial spaces, the need for rigidity is substantially lower and is reflected in the lack of fusions in their vertebral column.

## **The Ribcage and Sternebrae**

### ***Ribs***

A major component of the thoracic cavity (location of the heart and lungs) is the ribcage and the sternebrae (vertebrae of the sternum). In canines, there are generally 13 paired ribs, differentiated by method of sternal articulation. There are nine sternal or true ribs that have a direct articulation to the sternum via cartilage called costal cartilage (costal refers to the ribs). The remaining four ribs are asternal, lacking true connection to the sternum, and can be false or floating. A false rib does not directly connect to the sternum, rather the costal cartilage joins to that of the rib cranial (towards the head). The area of cartilage connecting false ribs to the sternum is referred to as the costal arch, which is the caudal boundary of the rib cage. Floating

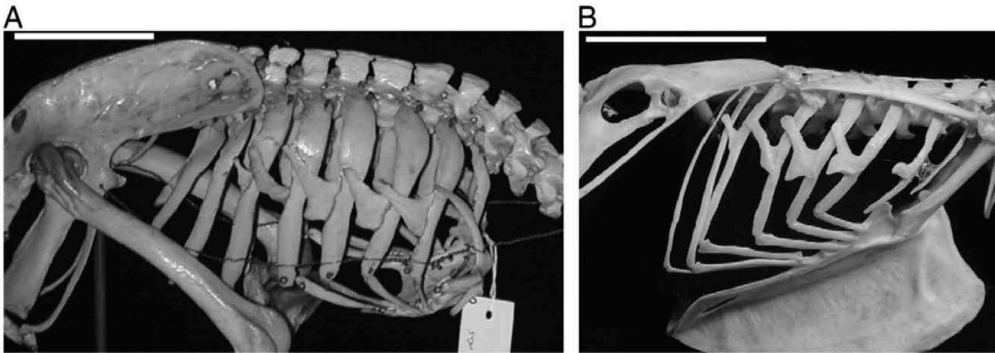
ribs are those without cartilaginous connection to the costal arch, and only articulate with the spine. Generally canine ribs 1-9 are sternal, 10-12 are false, and 13 is floating, though there can be variation in rib structure and occasionally rib number. The cartilaginous connection points along with musculature between the ribs forms a flexible rib cage that assists in respiration (Dyce, 2009; Troyer & Wilson, 2000).

Avian species have a ribcage to protect their thoracic cavity as well, with large sternal modifications and several bones forming the shoulder/pectoral girdle for the attachment of flight muscles. In contrast to mammalian sternal ribs, avian ribs are composed of a vertebral (dorsal) and sternal (ventral) aspects. Essentially, rather than having a cartilaginous rib to sternum connection and a costal arch, the sternal ribs form that connection point. The joint between sternal and vertebral ribs is assisted by cartilage, as is the joint between the sternum and sternal ribs. Following the naming system, the vertebral ribs articulate with the notarium and thoracic vertebrae, while the sternal ribs articulate with the sternum. Some of the vertebral ribs have additional processes called uncinat processes, that branch caudally at the midpoint of the rib, articulating flatly on the rib caudal to its origin. Uncinate processes in two species can be seen in Figure 11. These processes help maintain structural integrity of the ribcage throughout flight and respiration (Jacob & Pescatore, 2013). Additionally, the avian lungs are nonexpansile and attached to the thoracic vertebrae or notarium and the ribs. As the lungs are a rigid structure, the bony attachment points leave indentations on the lungs themselves. The solid structural lungs and ribcage function in gas exchange, while the air sacs act as bellows for inspired air (Maina, 2025). The modified avian sternum acts as a large point of attachment for flight muscles, which undergo substantial stress and strain. Having a nearly completely rigid ribcage allows for these muscles to be in a stable position at all times, further maximizing the efficiency of flight. The

terrestrial nature of canines supports the flexibility of the canine ribcage. This flexibility is also critical to the efficiency of canine respiration, as the muscles between the ribs assist in the inspiration of air.

### Figure 11

Images of Uncinate Processes of the Ribs



*Note.* Image showing the rib cage and uncinates in the great spotted kiwi (A) and the lorikeet (B). Image obtained from Codd, 2009.

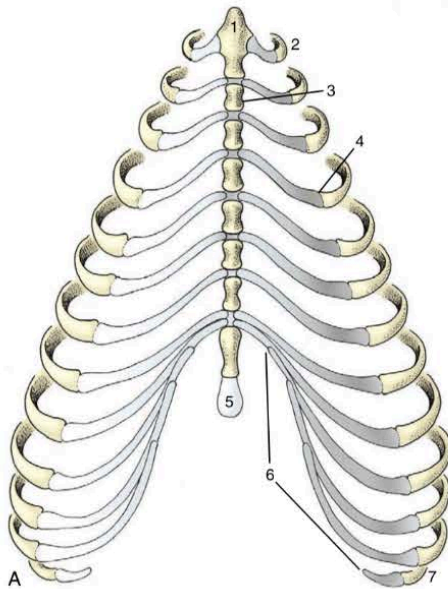
### *Sternebrae*

The canine ribs attach to the sternum, which is composed of various sternebrae (vertebrae of the sternum) and forms the ventral border of the thoracic cavity. The most cranial sternebrae is known as the manubrium, which acts as a point of muscle attachment for muscles that assist in neck and head movement. The most caudal sternebrae is the xiphoid process, continued via the xiphoid cartilage, acting to support the ventral body wall through the transition from thoracic to abdominal cavity. Sternebrae and rib structures can be viewed in the diagram of Figure 12. The true ribs (1-9) articulate with the sternum through cartilaginous connection, though only the costal cartilage of the first pair of ribs articulate directly with the sternebrae, specifically the manubrium. The following sternal ribs form cartilaginous joints between the costal cartilage (of the ribs) and the intersternbral cartilage (between sternebrae). The canine sternebrae contribute

to the protection of the thoracic cavity, and the ability for flexible, muscle motivated respiration (Broek et al., 2023).

**Figure 12**

Diagram of Canine Sternebrae and Associated Ribs



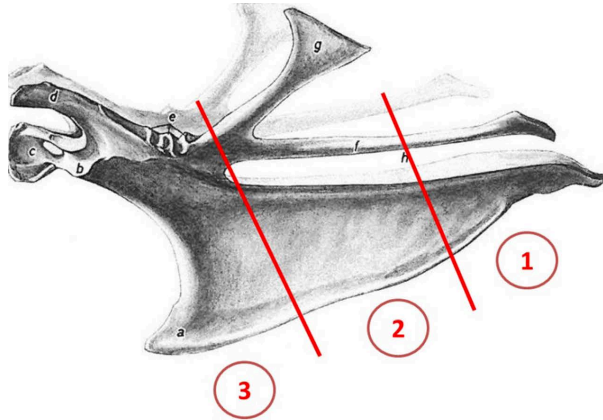
*Note.* 1-Manubrium, 2-first rib, 3-sternebra, 4-cartilage & bone junction, 5-xiphoid cartilage, 6-coastal arch, 7-floating rib. Diagram obtained from Dyce, 2009, p. 42.

The modified avian sternum, or keel, provides a large, flat surface area for flight muscles to attach. A diagram of the keel can be seen in Figure 13. This flat surface forms structural support for a large part of the ventral body wall, and is connected to the vertebrae by the previously described sternal and vertebral ribs, as seen in Figure 14. In the center of the sternum is the carina, which lies perpendicular to the sternum. The carina also provides surface area for muscle attachment, which is crucial for flighted birds (O'Malley, 2005). The pectoralis muscle is responsible for the strong downstroke of flight, which originates from the keel and furcula (clavicle) and attaches to the dorsal humerus. The muscle responsible for the upstroke is the

supracoracoideus muscle, primarily utilized during take-off, hovering, and at slow speeds. This muscle also originates from the keel bone, and attaches on the dorsal humerus (Biewener, 2011).

**Figure 13**

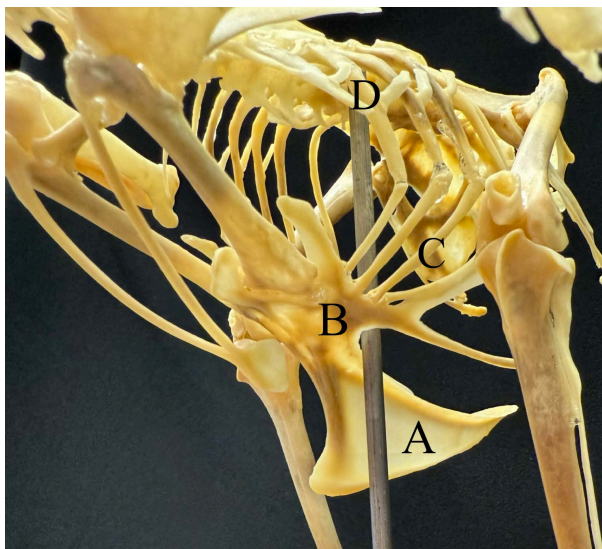
Diagram of a Chicken Keel Bone



*Note.* Lateral view of a chicken keel bone. 1-caudal keel, 2-middle keel, 3-cranial keel. Obtained from Thofner et al., 2020.

**Figure 14**

Image of Chicken Keel Articulation



*Note.* The modified avian sternum and articulations of sternal and vertebral ribs. A- Carina, B- Sternum, C- Sternal ribs, D- Vertebral ribs. Author's photograph.

### *Clavicle & Shoulder Girdle*

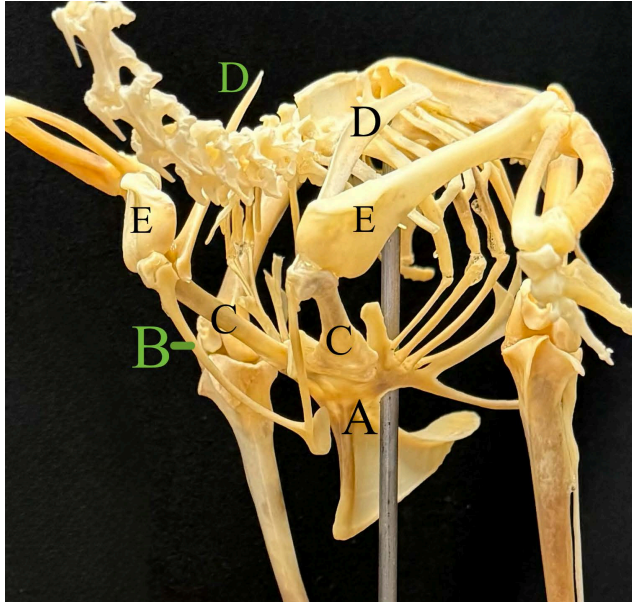
A clavicle bone may be present in the canine, though it does not articulate with the scapula, ribs, sternum, or other bony structures. If not present as a true bone, it can be formed by cartilage or fully absent. This rudimentary structure is found in the brachiocephalic muscle, connecting the thoracic limb (brachio-) to the head (-cephalic). The clavicle forms what is known as the clavicular intersection of the brachiocephalic muscle, allowing two separate functional units to exist within one large muscle. Found in the ventral region of the neck, this paired bone is still commonly present in many breeds and visible in radiographs (McCarthy & Wood, 1988). The shoulder girdle in the canine is composed of the scapula and the muscles that connect the forelimb to the trunk of the body. With no direct bony articulations between the forelimb and trunk, musculature is critical (Dyce, 2009).

In avians, the furcula is composed of the left and right clavicles. Commonly referenced as the wishbone, the furcula articulates with the right and left coracoid bone. The furcula, coracoid, scapula, and humerus form the shoulder or pectoral girdle, as seen in Figure 15 (Dyce, 2009). This structure is integral for flight, as it acts as an attachment point for the primary flight muscles, along with stabilizing the flight apparatus as whole (Hui, 2001). The previously mentioned supracoracoideus muscle has a tendon that passes dorsally over the shoulder girdle. This tendon utilizes a specific canal formed by the shoulder girdle, forming a pulley system to create the wing upstroke. This structure is called the osseous triosseal canal, and is made of the scapula, coracoid, and furcula. This canal is named based on the bone composition (osseous) and the number of bones forming it (tri-osseal). During takeoff, the supracoracoideus muscle contracts, the wing is pulled dorsally utilizing the shoulder girdle as a pulley. The pectoralis muscle then contracts, pulling the wing ventral (Biewener, 2011). The attachment points and

insertions of these flight muscles can be seen in Figure 16. The shoulder girdle and associated musculature is critical for efficient flight and function of the wings (Wu et al., 2024).

**Figure 15**

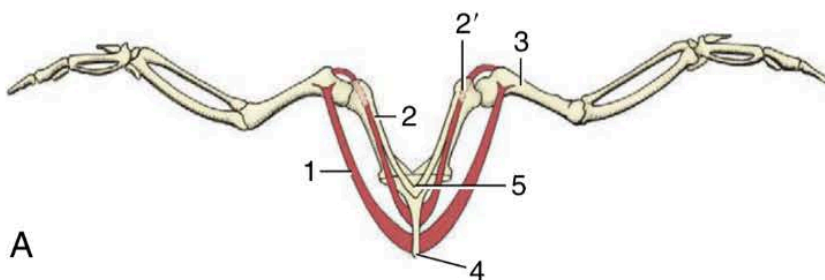
Image of Chicken Shoulder Girdle



*Note.* The chicken shoulder girdle. A- Keel, B- Furcula, C- Coracoid, D- Scapula, E- Humerus. Author's Photograph.

**Figure 16**

Diagram of Primary Flight Muscles



*Note.* 1-Pectoralis, 2-supracoracoideus, 2' - , 3-humerus, 4-sternum, 5-clavicle. Diagram Obtained from Dyce, 2009, p. 793.

## **The Pelvic Limbs**

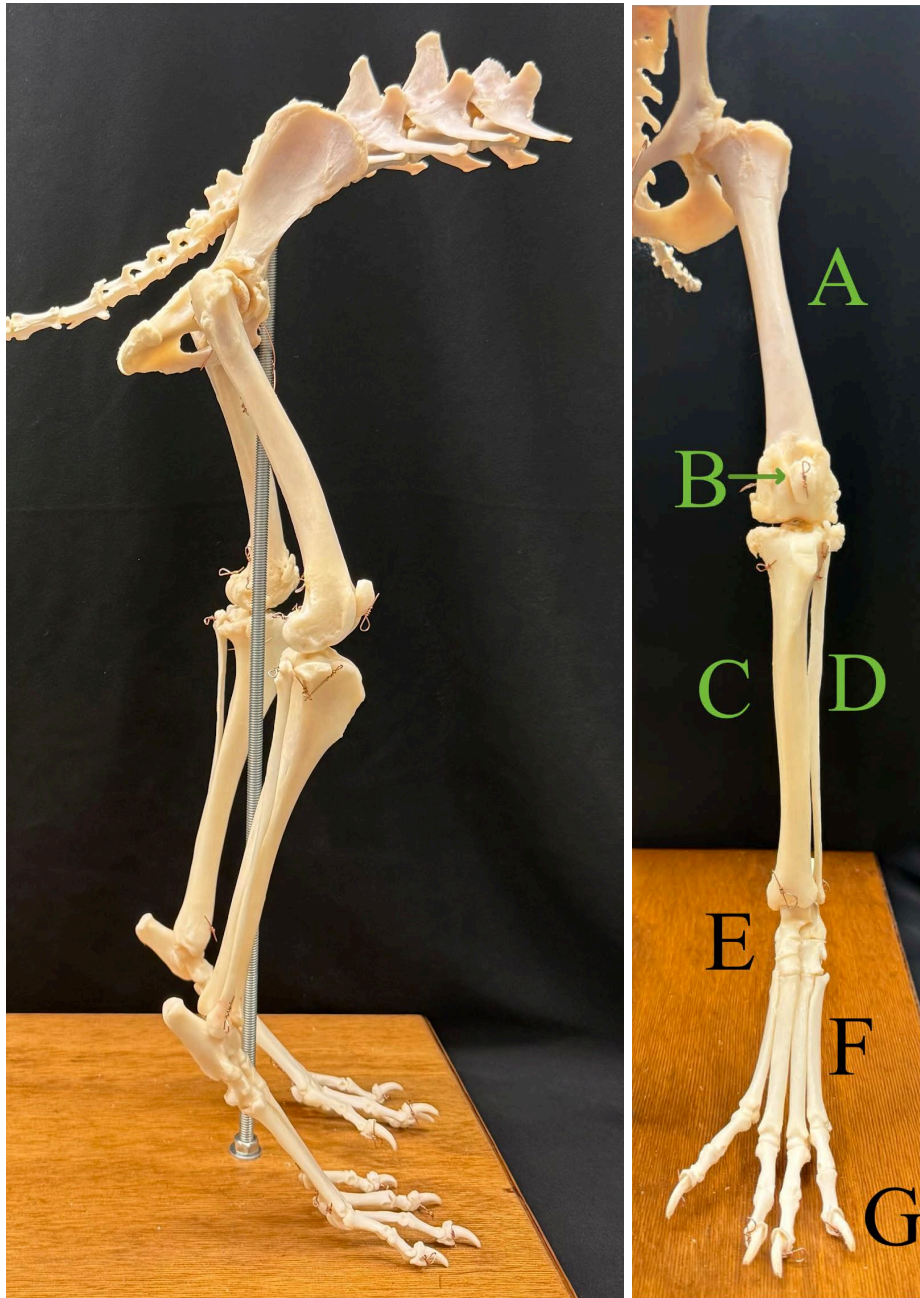
### ***Flow of Bones***

Having thoroughly covered the axial skeleton, it is time to branch to the appendicular skeleton, or the limbs. Comparing the hindlimbs of canine and avian species displays the main components of terrestrial locomotion, and how skeletal variation throughout the body allows avian flight. Beginning with the pelvic limb of the canine, as seen in Figure 17, the flow of bones proximal to distal (from the closest to the body to furthest from the body) begins with the pelvis, which has areas for the left and right femur bones to articulate. The pelvis articulates directly with the axial skeleton via the sacrum and vertebral articulation, as seen in Figure 8. At the distal end of the femur, there is a small bone called the patella (commonly known as the kneecap) that aids in joint stabilization and muscle attachment (Dyce, 2009; Yalin et al., 2025). The femur and patella articulate with the tibia and fibula. These are two long bones that run side by side to support the lower leg. The tibia is thick and medial and the fibula is much thinner and lateral. The tibia and fibula then articulate with the tarsal bones (there are seven total), forming the tarsus or hock region of the pelvic limb. There are two rows of tarsal bones, with the proximal row articulating with the tibia and fibula, and the distal row articulating with the metatarsals. The metatarsals are thin bones that begin the structure of each individual digit. Each digit is composed of three phalanges: the proximal, middle, and distal phalanges. The proximal phalanx articulates with the metatarsals, and the distal phalanx is partially covered by the toenail, hence the nail-like shape of the bone (Dyce, 2009). The digits are numbered medially to laterally (closest to midline to furthest from midline), with the dew-claw numbered I and the most lateral digit as V. While being non-functional and non-weight bearing, the dew claw is often reduced to

a proximal and distal phalange, if present. Digits II-V are functional and weight bearing, and each digit is composed of the three phalangeal components (proximal, middle, and distal).

**Figure 17**

Images of the Canine Pelvic Limb



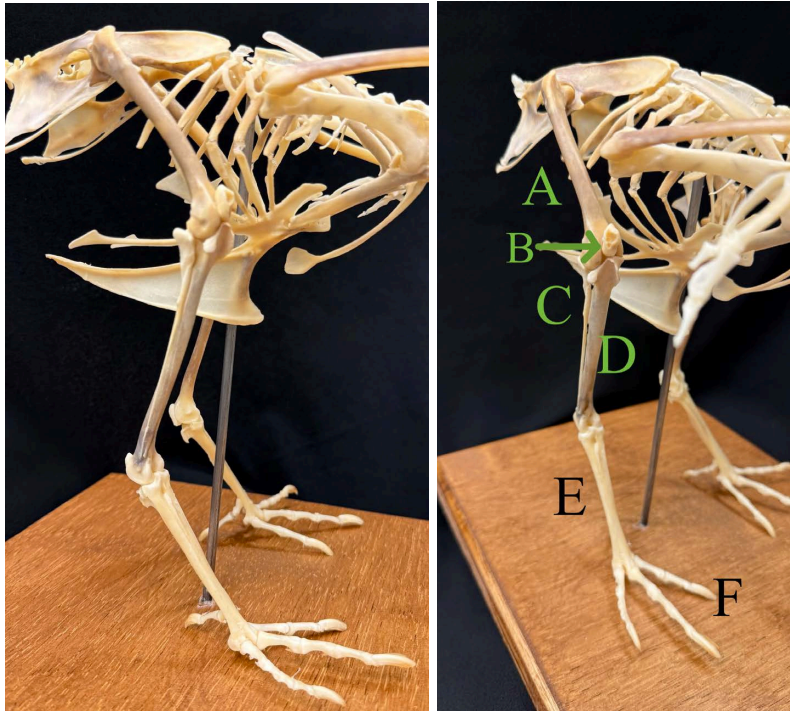
*Note.* The lateral (left) and Cranial (right) view of the canine pelvic limb. A- Femur, B- Patella, C- Tibia, D- Fibula, E- Tarsal bones, F- Metatarsals, G- Digits. Author's photograph.

In avian species the general pelvic limb structure remains the same, though there are several fusions to reduce weight and increase stability. The avian pelvic limb can be seen in Figure 18. Moving proximally to distally, the pelvic limb begins with the synsacrum, which also has areas for left and right femoral articulation. The femur is hollow, and in some species is pneumatized from the respiratory system (Moore & Schachner, 2025). Across avian species, there is variation in the presence of a patella. Some species have a bony patella located at the distal end of the femur, while others have patchy areas of cartilage where the patella would be located, or no patella-like structure at all. For example, chickens have a bony patella. When present, the patella acts as an area for muscle attachment (Regnault et al., 2014). Articulating with the femur is the tibiotarsus, which is a fusion between the tibia and the proximal tarsal bones. Proximally, the fibula is also present, and is fused to the proximal tibiotarsus. The fused fibula is incomplete, as it tapers off at the distal quarter of the tibiotarsus, as seen in Figure 18 labelled with the letter C. The tibiotarsus articulates with the tarsometatarsus, which is a fusion of the distal tarsal bones and the metatarsals. The four digits articulate directly with the tarsometatarsus. Similar to the canine, digits are also numbered medial to lateral, with the first often positioned more caudal than the rest. All digits are functional and weight bearing, though there are different digit conformations in different species (Dyce, 2009). Zygodactyl orientation is when digits II and III point cranially, with digit I and IV pointing caudally. Parrots and woodpeckers display zygodactyl orientation. Anisodactyl species have digits II, III, and IV pointing cranially, with digit I pointing caudally. Chickens and quail are anisodactyl, as seen in the chicken specimen of Figure 18. Additionally, some species (such as the osprey) are semi-zygodactyl, meaning they can move digit IV from a zygodactyl orientation to an

anisodactyl orientation. Anisodactyl and zygodactyl examples can be seen in the diagrams of Figure 19.

### Figure 18

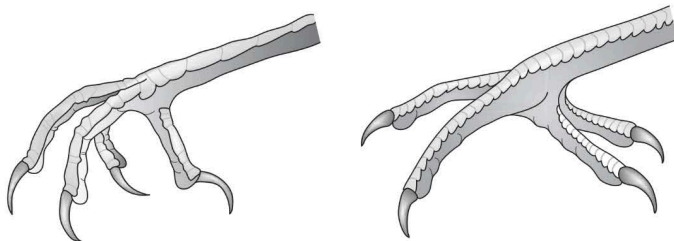
Images of Chicken Pelvic Limb



*Note.* The lateral (left) and cranial (right) views of the chicken pelvic limb. A- Femur, B- Patella, C- Fibula, D- Tibiotarsus, E- Tarsometatarsus, F- Digits. Note the presence of the patella. Author's photograph.

### Figure 19

Diagrams of Avian Digit Orientation



*Note.* Anisodactyl (left) and zygodactyl (right) orientations. Diagram obtained from O'Malley, 2005, pp. 112-113.

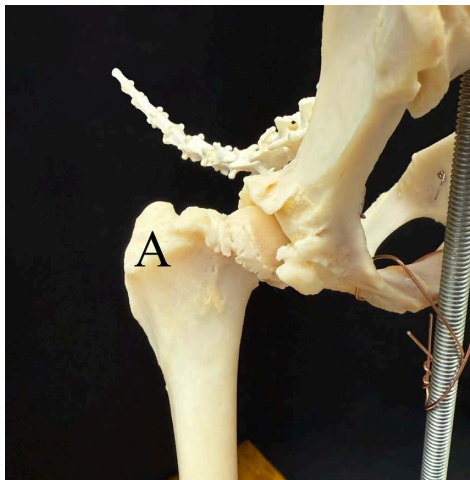
This digit orientation is highly related to each species lifestyle and habits. Bird species that are perched more than walking typically have anisodactyl orientation, while species that manipulate their food or climb may have a zygodactyl foot orientation (Botelho et al., 2014; Hofling & Abourachid, 2020). Digit and phalangeal numbers can vary across species, but chickens have four digits, with digit I, II, III, and IV having 2, 3, 4, and 5 phalanges respectively (University of Illinois Urbana-Champaign, n.d.).

### ***Limb Function***

The primary functions of the canine pelvic limb are locomotion and bearing approximately 40% of total body weight (Fish et al., 2020). As limbs that hold nearly half the body weight, and assist in locomotion, large musculature is required. When there is large musculature, there must also be areas for these muscles to attach. In the femur bone, there is a large process called the greater trochanter, that is lateral to where the femur articulates with the pelvis, as seen in Figure 20. The greater trochanter is a crucial muscle attachment point, providing surface area for gluteal muscles and hip extensors to attach (Dyce, 2009).

### **Figure 20**

Image of the Canine Hip Joint

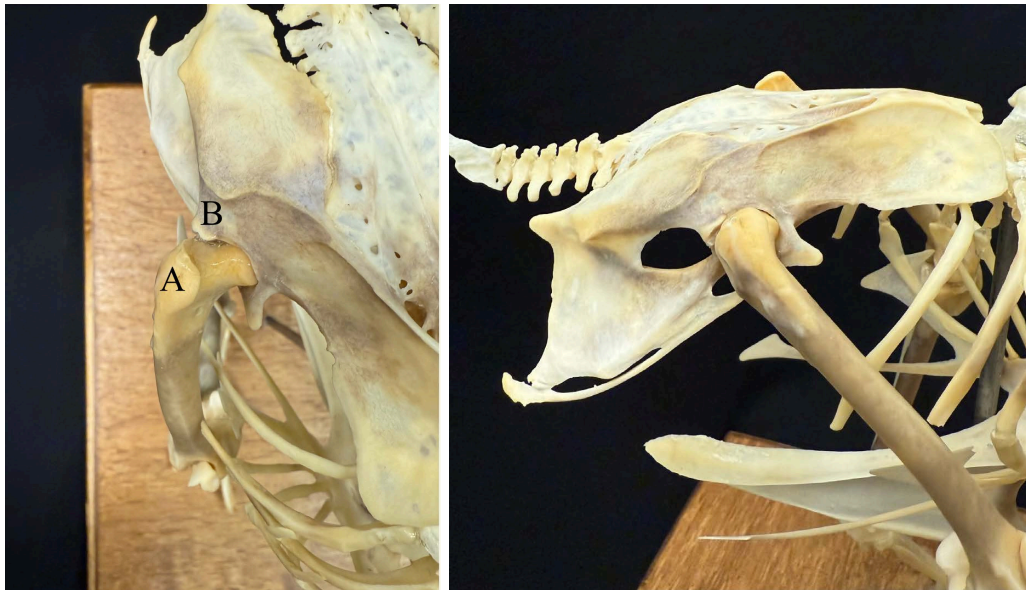

*Note.* The greater trochanter of the femur bone, labelled as A. Author's photograph.

Similar to the canine, avian pelvic limbs are also functional in locomotion and bearing weight. However, as bipedal animals, avian pelvic limbs bear 100% of their weight. The avian femur bone still has a greater trochanter for muscle attachment, however, the avian synsacrum has a similar structure called the antitrochanter, as seen in Figure 21.

**Figure 21**

Image of the Avian Hip Joint



*Note.* Dorsal (left) and lateral (right) views of the chicken hip joint between the femur and the synsacrum.

A- Greater trochanter of the femur, B- Antitrochanter of the synsacrum. Author's photograph.

The antitrochanter of the pelvis is located caudally to the hip joint on the lateral aspect. This structure articulates with the neck of the femur, and provides support in balance while walking, and to disperse stress on the femur due to a wider and more horizontal positioning compared to the canine hip joint. While walking, or in relaxed perching, each leg carries the bird's entire body weight. With a short tail that cannot assist in balance, the femur is held more parallel with the body to maintain balance and center of mass. Due to their wide abdomens and rib cage, the femur must be abducted (moved away from midline), to prevent contact with the rib cage and

abdomen. The antitrochanter helps stabilize this joint while bearing weight, such as in walking, and perching on either one or both legs (Hertel & Campbell Jr., 2007).

## **The Thoracic Limb**

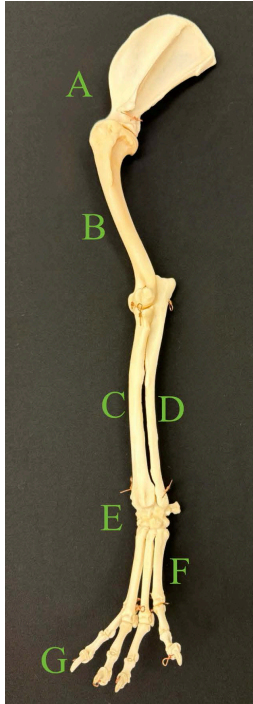### ***Flow of Bones***

The canine thoracic limb bears resemblance to the pelvic limb, with a similar flow of bones and function. Beginning proximally with the scapula, this triangular bone articulates with the humerus, and only the humerus. There is no bony connection between the thoracic limb and the trunk of the body in canines, therefore, attachment relies solely on musculature. The scapula has a large surface area for the musculature of the leg (intrinsic muscles) as well as the musculature of the trunk (extrinsic muscles). From the humerus, the radius and ulna articulate and run alongside each other in the forearm. Proximally, the radius articulates cranially and the ulna articulates caudally with the humerus. Distally, the radius articulates medially and the ulna articulates laterally with the carpal bones. The shape of both the radius and ulna allow rotation of the forearm. There are seven carpal bones that make up the carpus (commonly referred to as the wrist). Similar to the tarsal bones, the carpal bones are aligned in two rows with the proximal row articulating with the radius and ulna, and the distal row articulating with the metacarpals. The metacarpals are thin bones that begin the structure of the forelimb digits. There are four to five digits in the canine forelimb, with digit I being the medial dew-claw and digit V as the most lateral position. Mirroring the pelvic limb, the dew claw is non-functional and non-weight bearing. When present, the dew-claw of the thoracic limb is often reduced to just a proximal and distal phalange. Again, digits II-V are functional and weight bearing, with all three phalange components (proximal, middle, and distal). The distal phalanx is partially contained by the

thoracic claw, hence the claw shape of the bone (Dyce, 2009). Figure 22 displays a canine thoracic limb, from the scapula to the digits.

**Figure 22**

Image of the Canine Thoracic Limb



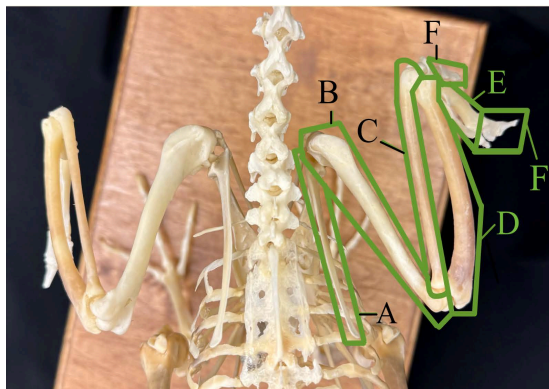
*Note.* Image of a canine left thoracic limb. A- Scapula, B- Humerus, C- Radius, D- Ulna, E- Carpal bones, F- Metacarpals, G- Digits. Author's photograph.

The avian thoracic limb bears resemblance to the avian pelvic limb in terms of fusions and flow of bones, while serving a drastically different function: flight. The scapula is an elongated triangular shape that articulates with the humerus, coracoid, and furcula in a large joint. These structures form the shoulder girdle, and articulate directly with the axial skeleton (Wu et al., 2024). The humerus is yet another common pneumatic bone of the avian skeleton, housing an outpouching of respiratory air sacs (Burton et al., 2023). The humerus proximally articulates directly with the scapula and the coracoid bones, and distally with the radius and ulna. The radius and ulna run alongside each other, with the radius being the shorter and thinner of the

two bones. The radius is located more cranially than the ulna proximally and distally, while maintaining some ability for rotation at the carpus through rotation of the distal wing (Baliga et al., 2019; Vazquez, 1995). Unlike the avian pelvic limb, where all tarsal bones are fused, two carpal bones remain free. The radial and ulnar carpal bones articulate between the radius and ulna and the carpometacarpus. As the name suggests, the carpometacarpus is a fusion of the remaining carpal bones and the metacarpals. This structure begins the attachment of primary flight feathers that extend to the most distal digits (Hieronymus, 2016). There are only three digits on each thoracic limb, with varying hypotheses on the evolution of the reduced digits. Some sources support the claim that the remaining digits are II, III, and IV, while others support the remaining digits being I, II, and III (Xu & Mackem, 2013). The first remaining digit is called the alula, and is the most proximal digit. It houses one phalange and two to six feathers. This structure primarily assists in low velocity and high angular flights (Dyce, 2009; Lee et al., 2015). The second remaining digit has two phalanges, and the third remaining digit has one phalanx (Dyce, 2009).

### Figure 23

Image of Avian Wing



*Note.* Dorsal view of the chicken, displaying both wings extending from the body. A- Scapula, B- Humerus, C- Radius, D- Ulna, E- Carpometacarpus, F- Digits. Author's photograph.

### ***Limb Function***

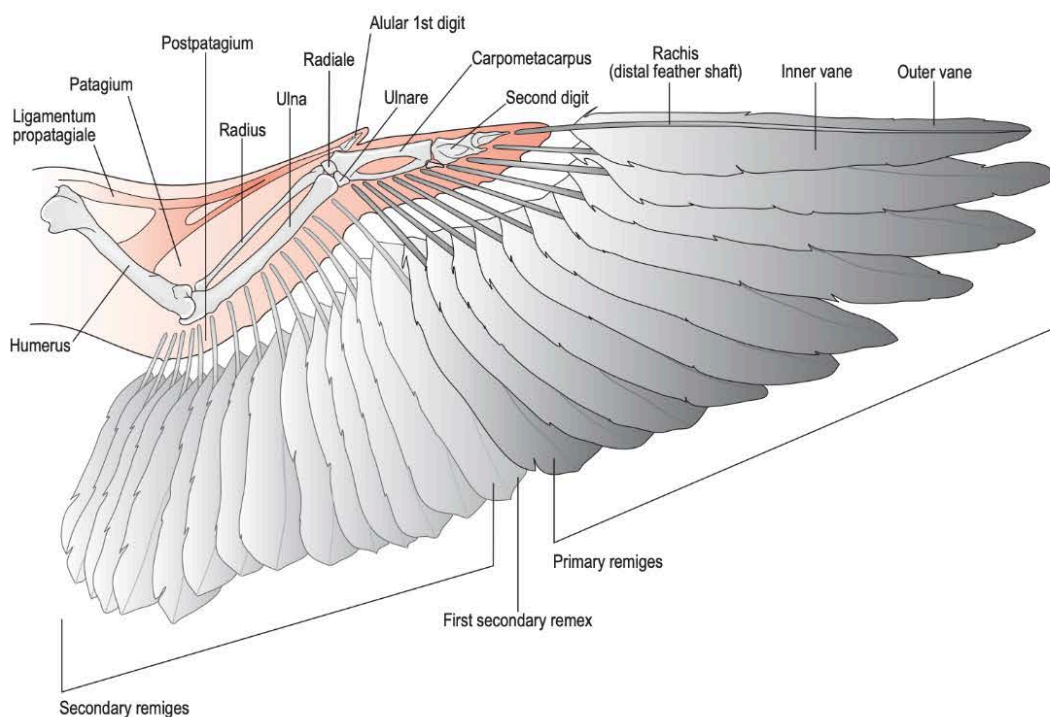
In the canine thoracic limb, the main functions lie in locomotion and bearing weight. A large component of variation between the weight distribution from pelvic to thoracic limb is positioning of the head. The thoracic limbs provide direct support for approximately 60% of the canine body weight. The weight of the head and chest falling entirely on the thoracic limb is likely the cause for the weight disparity of the pelvic versus thoracic limbs (Fish et al., 2020). Musculature is also critical in the forelimb, both for locomotion and providing attachment to the trunk. Due to the lack of bony articulations between the forelimb and the trunk, musculature of this region is divided into extrinsic (muscles extending from the forelimb to the trunk) and intrinsic (muscles remaining only in the forelimb). The scapula provides many attachment points for both sets of muscles. The intrinsic and extrinsic musculature allows the forelimb to act as a strut to support the trunk in faster gaits. There are also aspects of elasticity in the musculature that assist in the structure of the forelimb acting as a strut and shock absorber (Walter & Carrier, 2007; Williams et al., 2008).

The avian thoracic limb functions in aerial locomotion rather than terrestrial locomotion. Flight is made possible through the extensive skeletal modifications of microanatomy, fusions, pneumatization, musculature, and efficient respiration. Though not all avian species demonstrate flight, it has allowed the development of avian species to branch into nearly every habitat on Earth (Rayner, 1988). The feathers of the wings that are critical for flight are the primary and secondary feathers, along with their covert feathers that protect the proximal feather. Primary feathers are the most distal wing feathers, while secondaries are just proximal to the primaries. Flight feathers are attached to the wing and each other by musculature and ligaments. In addition

to providing attachment points for feathers, the musculature of the forelimb also facilitates the wing movements utilized in avian flight (Hieronymus, 2016).

### Figure 24

Diagram of Avian Wing



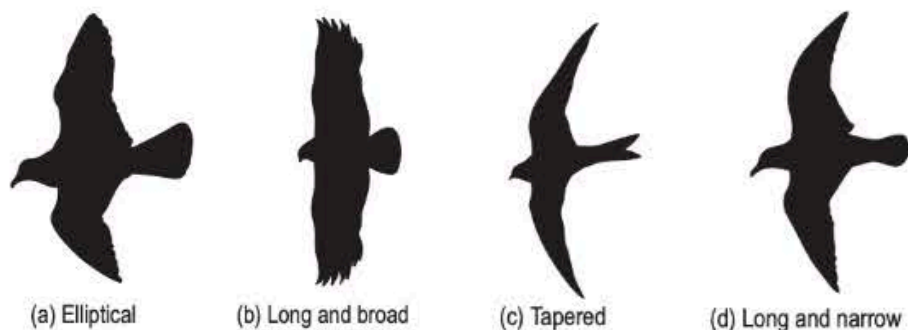
*Note.* The diagram displays feathers, skeletal structures, and soft tissue structures. Diagram obtained from O'Malley, 2005, p. 152.

These feathers (and previously identified traits) allow for the wing to act as an airfoil, creating a lift force underneath the wings that supports flight. The flapping component of flight counteracts drag force with thrust, which is produced by the pectoralis and supracoracoideus muscles of the keel and shoulder girdle (Wu et al., 2024). The variation in ecology of species of birds changes the utility of flight; some birds soar, while others are highly maneuverable. These specializations are supported by wing shape, wing size, and body size. For example, species that inhabit the open skies tend to have long, pointed wings, while species inhabiting densely cluttered areas tend

to have shorter, rounded wings for greater maneuverability (Rayner, 1988). Variations in wing shape can be seen in Figure 25.

**Figure 25**

Diagram of Common Wing Shapes



Note. Variations in wing shape displayed. Diagram obtained from O'Malley, 2005, p. 108.

## The Respiratory System

### Structures of Respiration

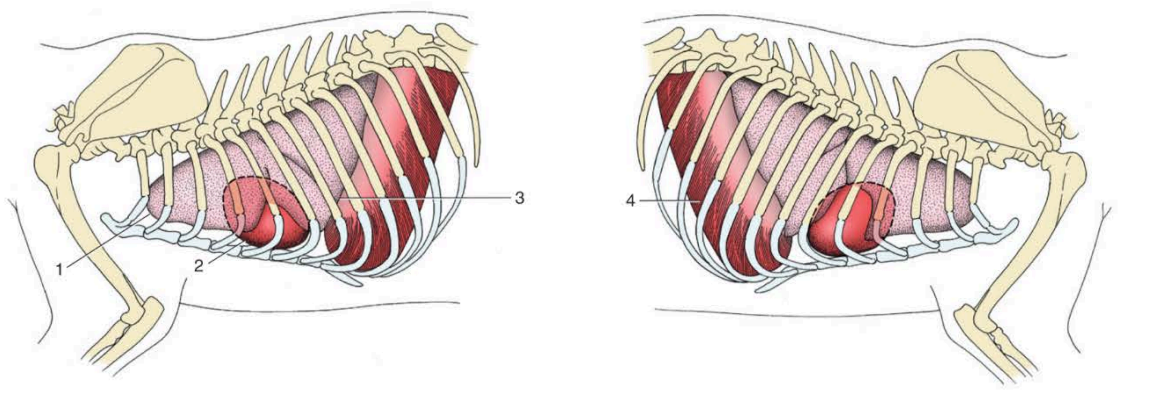
#### *Canine Respiration*

Moving from bones into breathing, the canine respiratory system is bidirectional, meaning air only requires one cycle of breathing (inhalation, exhalation) to fully pass through the respiratory system. Inhalation causes oxygenated air to pass through the external nose and nostrils (nares), move through the nasal passages, into the pharynx, larynx, and into the trachea. These structures compose the upper respiratory pathway. The trachea divides into two bronchi once in the thorax (chest), which will further branch within the right and left lungs into bronchioles, alveolar ducts, alveolar sacs, and alveoli. These branchings of the bronchi compose the lower respiratory pathway. Gas exchange occurs between the alveoli and pulmonary capillaries, which is the transfer of oxygen from the air within the lungs into the bloodstream, and carbon dioxide from the bloodstream into the air within the lungs. After gas exchange,

exhalation occurs. The newly deoxygenated air will pass from the alveoli to the external environment following the same pathway of inhalation, in reverse (Dyce, 2009).

**Figure 26**

Diagram of Canine lungs and Heart



*Note.* Diagram displaying where the lungs are located within the canine body on the left side (left) and on the right side (right). 1-Apex of the left lung (most cranial portion), 2-heart, 3-basal border of lung (base of the lung), 4-muscular diaphragm. Diagram obtained from Dyce, 2009, p. 423.

### ***Avian Respiration***

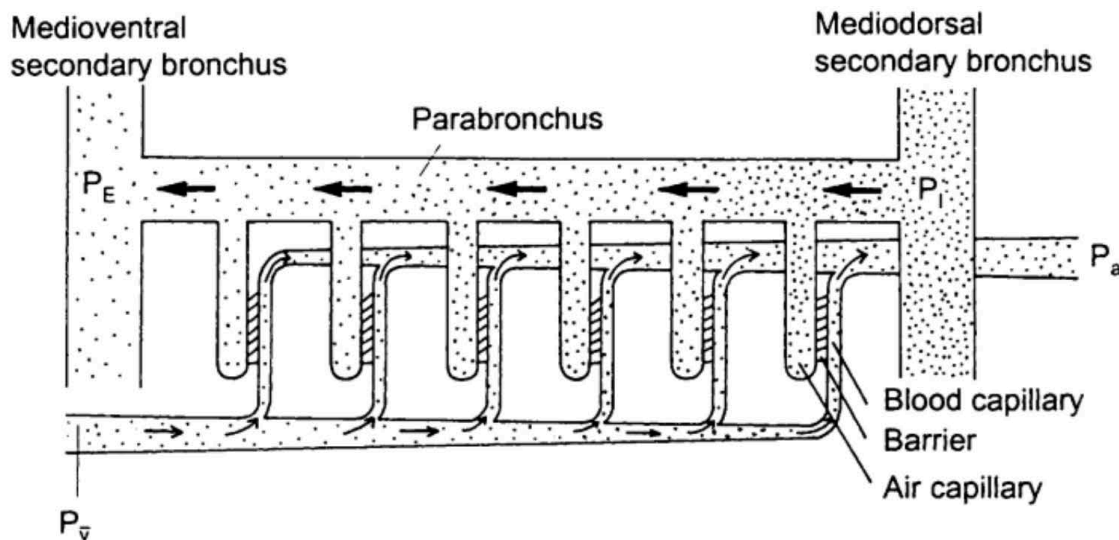
The avian respiratory system is very different to the mammalian respiratory system. Rather than utilizing bidirectional air flow (inspiration to fill the lungs, followed by expiration to empty the lungs) avians utilize a unidirectional or continuous flow of air. This is made possible by their air sacs that act as an extension of their respiratory system. With continuous air flow in avians, one full respiratory cycle is an inhalation, exhalation, another inhalation, and a final exhalation. On the first inhale, air flows through the body and into the caudal thoracic and abdominal air sacs. From the outside environment, air enters the nares (nostrils) and nasal sinuses, and flows into the trachea. The trachea bifurcates into a left and right primary bronchi. Once in the lungs, the primary bronchi are renamed to mesobronchi. Air travels passively

through the lungs via mesobronchi and into the caudal thoracic and abdominal air sacs. At this point in respiration, the air is still oxygenated and no gas exchange has occurred. During the first exhale of the cycle, air in the caudal thoracic and abdominal air sacs moves into the lungs through the secondary bronchi and passes through parabronchi for gas exchange. The lungs are located on the dorsal aspect of the body cavity, firmly attached to the vertebrae and ribs, with permanent impressions from the bony structures surrounding them. Unlike the canine lungs, avian lungs are non-expansile and supported by dense connective tissue, functioning only in gas exchange. Parabronchi within the lungs are connected to the air sacs with secondary bronchi, named based on their location in the body. The mediodorsal secondary bronchus allows air to flow from the caudal thoracic and abdominal air sacs into the parabronchi. The capillaries carrying deoxygenated blood run parallel and opposite to the parabronchi allowing a countercurrent exchange of oxygen and carbon dioxide, as seen in Figure 27. Due to this layout, it is possible for the post-parabronchi blood to have higher oxygen content than the air entering the parabronchi (Fedde, 1998). After gas exchange and during the second inhale of the cycle, the air from the parabronchi travels to the cranial thoracic, cervical, and clavicular air sacs via the medioventral secondary bronchus. With the final exhale of the cycle, the air passes back through the primary bronchi, the trachea, and back into the environment through the nares (Maina, 2022). Postcranial skeletal pneumaticity is a unique aspect of the avian respiratory system that is the extension of air sacs into surrounding bones. The level of PSP differs among avian species, ranging from a lack of pneumaticity (apneumatic) to a nearly entirely pneumatic skeleton (hyperpneumatic). Avians that are apneumatic include birds like penguins and kiwis, while hyperpneumatic avians include vultures and pelicans. The vertebrae, humerus, sternum, and pelvic girdle are common skeletal structures that have aspects of pneumaticity, such as

diverticula of air sacs. Species variations are generalized, as there can be variations in pneumaticity of individual birds from the same species. It is thought that PSP benefits avian species by reducing mass to lower the energy requirements for movement. In theory, when the bone is filled with air rather than bone marrow, the body is lighter and therefore less energy is required in flight and locomotion. However, few studies have quantified any decrease in body mass from pneumaticity, while Moore & Schachner (2025) found birds with pneumatic skeletons weigh just as much as apneumatic birds of the same size. There are several other hypotheses of pneumaticity, with little data supporting any hypothesis in particular (Moore & Schachner, 2025).

**Figure 27**

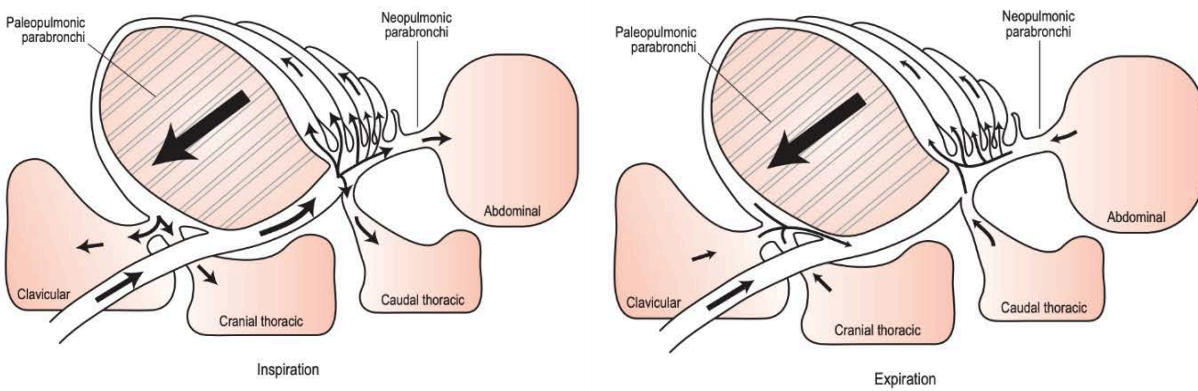
Diagram of the Avian Counter-Current Gas Exchange



*Note.* Diagram showing the air within the lungs flows to the left, while blood within capillaries flows to the right. Diagram obtained from Fedde, 1998.

**Figure 28**

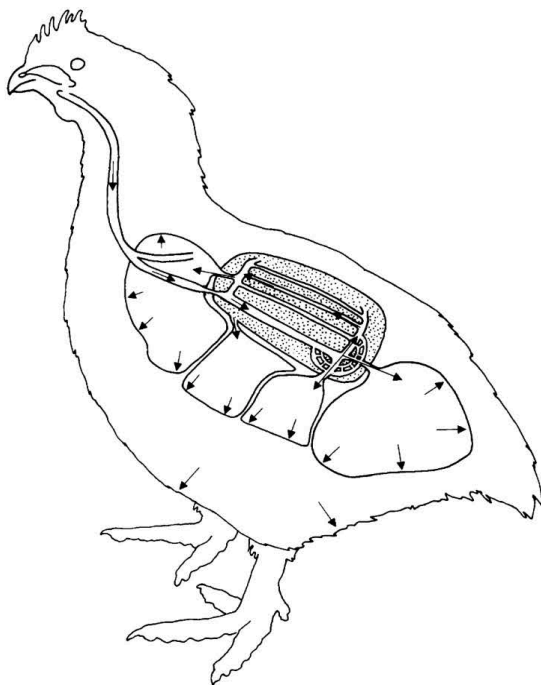
Diagram of the Avian Lungs and Air Sacs



*Note.* Avian inspiration (top) and expiration (bottom). Diagram obtained from O'Malley, 2005, p. 123.

**Figure 29**

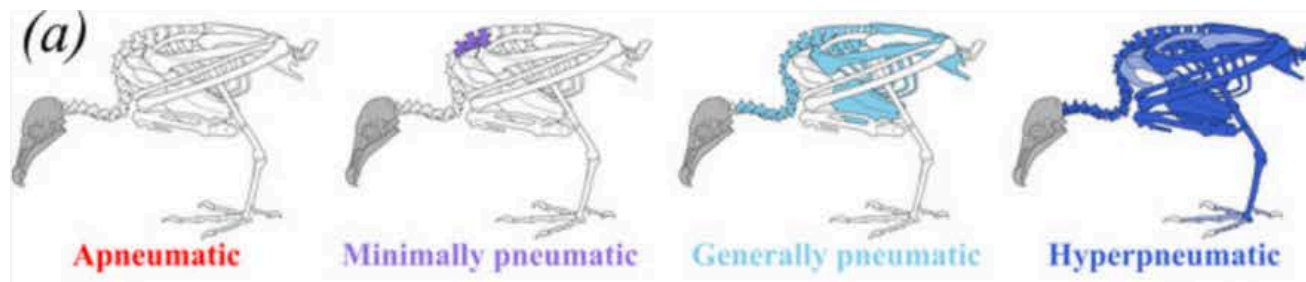
Diagram of Chicken Respiratory System



*Note.* Location of the lungs and air sacs within a chicken. Arrows describe movement of the body and air during inspiration. Diagram obtained from Fedde, 1998.

**Figure 30**

Pneumaticity in Various Avian Species



Note. (a) displays general variations in postcranial skeletal pneumaticity across avian species. Diagram obtained from Moore & Schachner, 2025.

## Mechanisms of Ventilation

### *Canine Ventilation*

While assisted by musculature, canine respiration relies on partial pressures within the lungs (specifically the alveoli). This occurs when the muscles associated with respiration contract, enlarging the thorax, decreasing alveolar pressure, allowing environmental air to flow into the lungs. Relative pressures within the lungs assist in respiration due to the expansive nature of lung tissue. The ability to mechanically expand and contract allows the lungs to ventilate air flow along with performing gas exchange (Dyce, 2009). The primary respiratory muscle is the diaphragm, which forms the separation between the thoracic and abdominal cavity. The thoracic cavity is enlarged when the diaphragm contracts, causing a decrease in alveolar pressure. External intercostal muscles (muscles between the ribs on the lateral aspect) and other abdominal muscles assist with inhalation. On exhalation, these muscles relax, reducing the size of the thorax which increases the alveolar pressure, allowing lung (stale) air to flow into the environment from the lungs. A majority of the time, exhalation is passive and requires no muscle contraction, though intense exercise and some diseases can lead to muscle assisted exhalation.

The muscles utilized in these scenarios are the internal intercostal muscles (muscles between the ribs on the medial aspect), and other abdominal muscles. When exhalation is active, the contraction of muscles reduces the size of the thorax, increasing alveolar pressure. This increased pressure allows air in the lungs to flow back into the environment. In both passive and active exhalation deoxygenated air (stale air) within the lungs flows back out into the environment. However, some air remains in the lungs. This air is called residual air, and it prevents the lungs from collapsing after exhalation. While each breath introduces oxygenated air, not all air within the lungs will be oxygenated. This is due to residual air as well as alveolar dead spaces, or spaces in the alveoli that do not have blood supply (Ewart, 2020).

### ***Avian Ventilation***

In addition to this heavy variation in structure, the mechanisms of avian breathing are also different. With fixed non-expansile lungs and lacking a muscular diaphragm, the avian lungs have very little change in volume during respiration (Maina, 2022). While canine lungs act as a ventilator and perform gas exchange, avian lungs carry out gas exchange and the air sacs act as ventilators. Musculature and pressure are utilized to inflate and deflate the air sacs, rather than the lungs (Harvey & Ben-Tal, 2016). As both inspiration and expiration are active processes in avians, both require the contraction of intercostal muscles to facilitate the flow of air within air sacs. The uncinat processes of the vertebral ribs are greatly associated with the intercostal muscles, and in turn are greatly associated with respiration. The musculature associated with the ribs and uncinat processes rotate the sternum ventrally on inspiration, increasing the volume of air sacs and facilitating air flow into the air sacs. On expiration, abdominal musculature contracts and rotates the sternum dorsally, decreasing the volume within the air sacs and ventilating air through the body (Codd, 2009). When air from the caudal air sacs enters the lungs, it has a high

concentration of oxygen and a low concentration of carbon dioxide. After passing through the parabronchi and undergoing gas exchange, all air in the cranial air sacs have low oxygen concentrations and high concentration of carbon dioxide (Maina, 2025). This differs from canines, as all air in the avian lungs passing through the area of gas exchange is oxygenated, rather than a mixture of oxygenated and deoxygenated air entering the canine alveoli. Each aspect of the avian lung contributes to the high level of efficiency, and their ability to fly at altitudes with low oxygen concentrations (Mania, 2025).

### **Pathologies**

With an in depth foundation built for both canine and avian skeletal and respiratory systems, the following sections will explore how the anatomical variations impact injuries of the skeletal system and diseases of the respiratory system. Structural differences across species leads to differences in the presentation, diagnosis, prognosis, and treatment of injuries and diseases.

### **Skeletal Injuries**

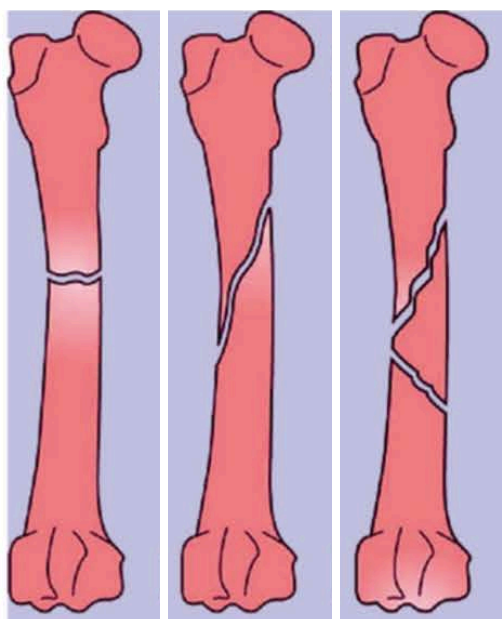
#### ***Types of Fractures***

When considering skeletal injuries, fractures are often the first thing to come to mind. A fracture in simple terms is a broken or cracked bone. They can be caused from stress injuries (too much pressure in an unnatural direction or magnitude), or associated with conditions that create weakness in the bones, such as egg-bound avians. There are many different ways that bones can break, leading to many classifications of fractures themselves (Johns Hopkins, n.d.). Common fracture types include transverse, oblique, comminuted, and compound. A transverse fracture is simply a break perpendicular to the bone, while an oblique fracture is at an angle within the bone. A comminuted fracture is one of extreme pressure. Rather than having one single break forming a fracture, comminution is the fragmentation of bone into two or more pieces. Several

breaks along the bone form a shattering effect, causing many small bone pieces within the fracture itself. These three fracture types can be seen in Figure 31. With several fragments comes complex healing and surgical techniques that often require more hardware than a simple transverse or oblique fracture (Filardi, 2019). Lastly, a compound fracture, or an open fracture, has exposure to the external environment. This exposure is often paired with soft tissue trauma. Open fractures are more likely to have complications due to injured tissue surrounding the injury, as well as the ability of external debris and bacteria to enter the wound and deep tissue. A compound fracture can be paired with other fracture classifications, for example, an oblique displaced compound fracture. This would refer to a misaligned fracture at an angle that is open to the environment. This can happen if one end of the fracture is sharp, and can cut through tissue to the open air (Sop & Sop, 2023). Compound or comminuted fractures in avian pneumatic bones introduce the concern of damage and infection to the respiratory system, which bears some resemblance to multiple rib fractures of the canine.

**Figure 31**

Diagram of Fractures



*Note.* Transverse (left), oblique (middle), and comminuted (right) fractures shown on the femur. Diagram obtained from Bigham-Sadegh & Oryan, 2014.

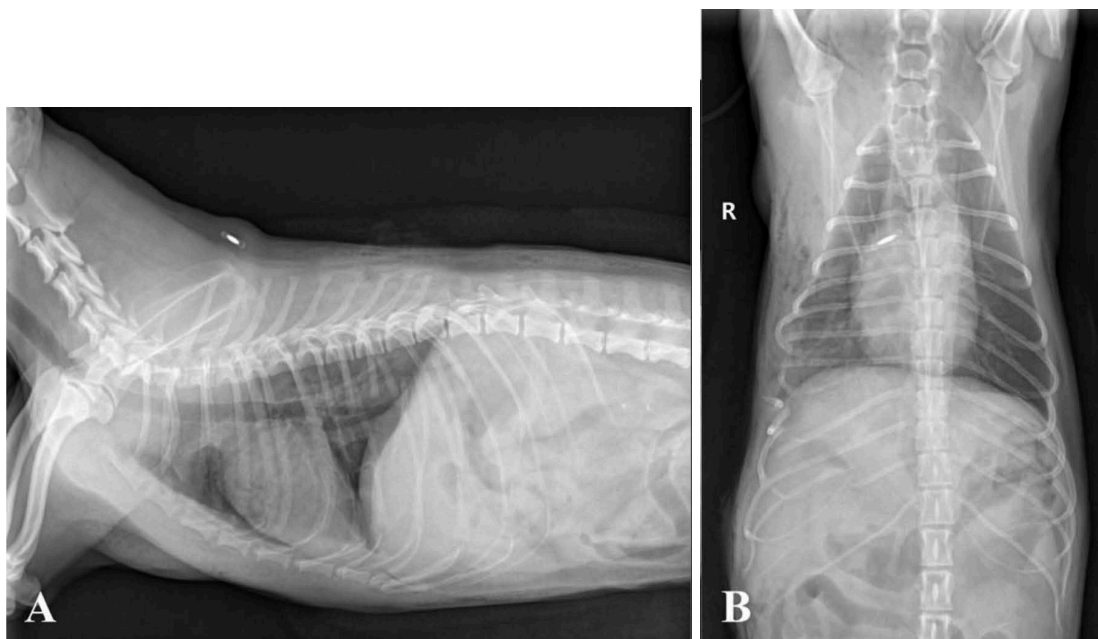
### ***Fractures in Canines***

Fractures in dog species are commonly due to trauma, such as vehicle collisions, gunshots, falls, or other injuries. The healing process of canine bones can take two pathways: indirect or direct. Indirect healing, or secondary healing, is typically non-surgical and is the most common way for fractures to heal. After the fracture occurs, a cartilaginous callus is formed, which later is replaced with bone. The bony callus is then remodeled into mature bone with a medullary cavity. Direct healing requires the fracture to be reduced (placed back into anatomical position), and fixed in a stable position. Often this form of healing is surgical, utilizing bone plates or intra-medullary pins to hold each side of the fracture in place. Direct healing bypasses the formation of a bony callus, jumping directly to the modeling of mature bone due to the stabilized positioning (Marsell & Einhorn, 2012). When repairing fractures with surgical procedures, emphasis is placed on preserving bone vascularization and remaining minimally invasive (Pozzi et al., 2021). While long bones like the femur and tibia are commonly fractured, bones within the axial skeleton experience fractures as well (Jain et al., 2018). In the rib cage, fractures can lead to less effective respiration due to their structural importance, along with increased susceptibility to secondary infections. Flail chest is a term for three or more fractured ribs in a row that have fractures in two or more spots, as seen in Figure 32 and 33. Flail chest can include any classification of fracture, and may include different classifications from rib to rib. This condition often requires mechanical ventilation due to structural damage to the ribs, which act as muscle attachment points for critical respiratory musculature. This condition has a guarded prognosis. The fractured ribs can be treated with surgical fixation, utilizing metal or biodegradable implants. Flail chest, when not treated surgically, can heal, but the ribs may heal in

non-anatomical placements or with deformities, which can create further complications for respiration and quality of life (Huang et al., 2014; Li et al., 2023).

**Figure 32**

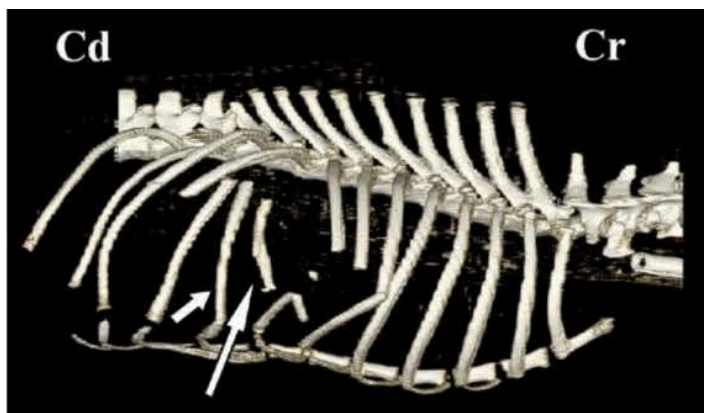Radiographs of Canine Flail Chest



*Note.* Radiographs displaying fractured 6th-11th right ribs. Radiographs obtained from Ahn et al., 2016.

**Figure 33**

3D Model of Canine Flail Chest



*Note.* 3D model displaying fractured 6th-11th right ribs. Modeled after the fractures in Figure 32. Model obtained from Ahn et al., 2016.

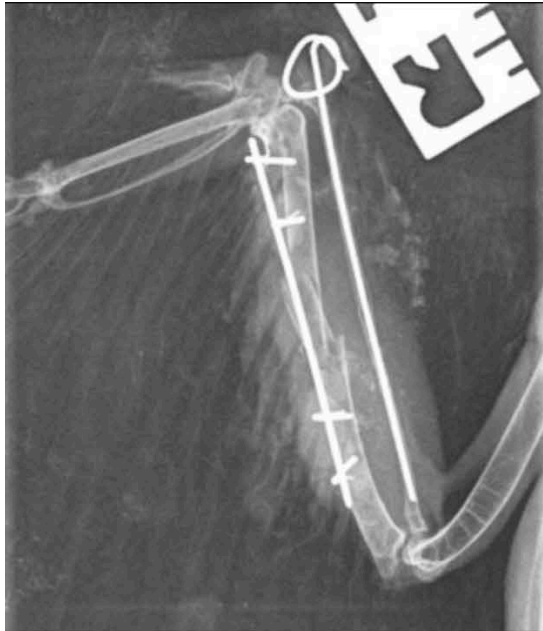
### *Fractures in Avians*

Fractures in bird species are very similar to fractures in canines, however, the pneumatic nature of avian bones make fractures more dangerous and more complex to treat. Fractures are commonly seen across many species of birds, and are diagnosed in approximately half of all raptors admitted to rehabilitation facilities (Coutant et al., 2022). In an avian fracture, the healing process involves forming a callus, which begins with cartilage forming around the fracture, that is eventually replaced by bone (Espinosa et al., 2025). These calluses form both from the inside of the bone (endosteum), as well as on the surface of the bone (periosteum), with the endosteum forming a majority of the callus in fractured pneumatic bones (Kayikci et al., 2019). A major difference from canines is the healing period. A stable fracture can heal in as little as three weeks. Depending on the severity of the fracture, displacement, location, and if it is open, some fractures can be treated with cage rest or simple bandaging techniques, while others require surgical intervention and placement of pins or wiring (Kayiki et al., 2019). In surgical techniques, a long pin may be placed through the bone's intramedullary space that may or may not be attached to an external stabilization mechanism, as seen in the radiograph of Figure 34 (Bueno et al., 2015).

In pneumatic bones, the medullary cavity is filled with air rather than vascularized bone marrow, leading to fewer nutrients delivered to the bone. This lack of vascularization is why pneumatic fractures take longer to heal, as nutrients are the limiting factor for callus formation (Coutant et al., 2022). Compound or comminuted fractures in pneumatic bones are especially dangerous due to the heightened risk of rupturing an air sac. A ruptured air sac can lead to air underneath the skin, also known as subcutaneous emphysema, which can cause discomfort and increase risk of secondary infections (Petevinos, 2006).

**Figure 34**

Radiograph of an Intramedullary pin in a Fractured Radius



*Note.* Radiograph displaying a fractured right radius & ulna in a Sparrow hawk, with a surgically placed intramedullary pin. Image obtained from Carrasco, 2019.

Over half of fractures in wild birds are compound, due to the lack of soft tissue support, especially in distal bones, such as the radius and ulna, that are only protected by tendon, skin, and feathers. This is especially dangerous in pneumatic bones due to access to the respiratory system. As open fractures expose the bone and wound to external debris and bacteria, the respiratory tract as whole is also exposed in pneumatic bones with ruptured air sacs. This exposure can lead to systemic respiratory infection, or even bone infection (Williams, 2002). In addition to fractures within the wings, there can also be fractures to the shoulder girdle, which are crucial in assisting flight muscles. Fractures to the coracoid or furcula can be treated with bandaging and cage rest, or surgically, with mixed results on which technique has a better outcome (Holz, 2008; Scheelings, 2014).

While less common, fractures to the axial skeleton are also possible. Fractures to the keel bone are widely described in the poultry field, and are a large welfare concern. Theories surrounding the high rates of keel fractures include trauma, underlying conditions, or high egg production. Most often the fracture is at the caudal tip of the keel, with ranging degrees of callus formations (Thofner et al., 2020). High egg production is a thought when considering avian fractures due to the high calcium content in egg shells. Female avian species have weakened bones when producing eggs due to the replacement of dense compact bone with calcium rich medullary bone to assist in forming eggshells. Therefore, hens that have a higher production of good quality eggs, often have lower bone quality, leading to a higher susceptibility to fractures (Afonso-Carrillo et al., 2021).

## **Respiratory Diseases**

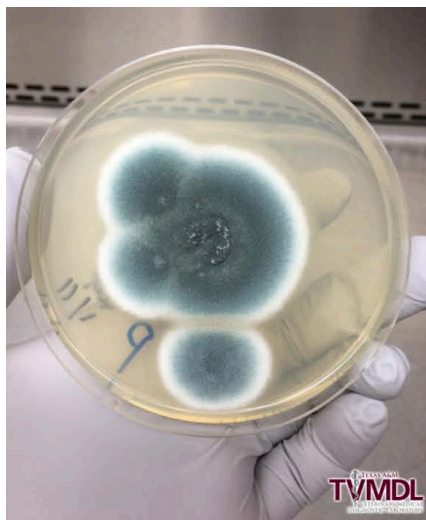### ***Aspergillosis Infection***

Moving into respiratory specific illnesses, aspergillosis is a fungal infection that can seriously impact many animal species including canines and avians. It is contracted by environmental exposure such as inhalation, ingestion, or direct contact to the fungal spores. Inhalation is the primary method of infection, with other pathways causing infection much less frequently. The *Aspergillus* genus of fungi is large (over 260 species), and most commonly found in areas of organic matter, such as soil, leaf litter, moldy crops, or moldy feed. Despite its vastness, less than 20 species are disease causing, with *Aspergillus fumigatus*, as seen in Figure 35, most commonly causing infection in mammals and birds. Animals that have an immunocompromised status are at higher risk for contracting this disease, increasing the risk for aspergillosis as a secondary infection. Despite the commonality of the fungus, the severity of the

disease is largely impacted based on the anatomy of the animal that contracts the fungus (Tell et al., 2019).

**Figure 35**

Image of Aspergillosis Growth on a Plate.

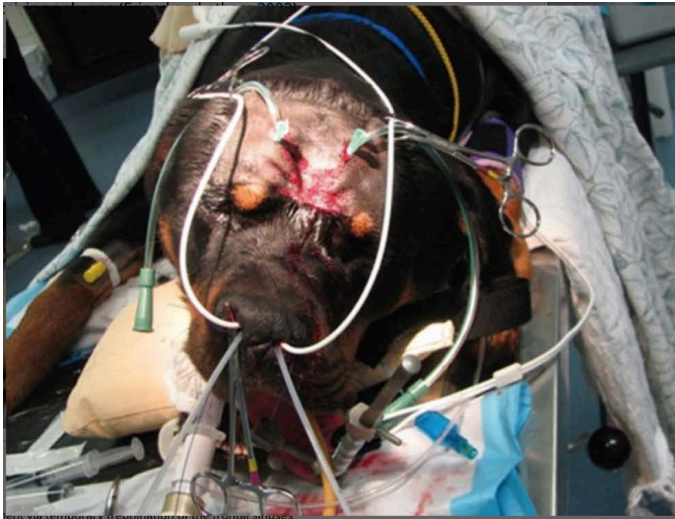

*Note.* *Aspergillus fumigatus* growing on a plate. Image obtained from Edwards & Paul, 2024.

When canines contract aspergillosis, the most common presentation is seen in the form of sinonasal aspergillosis (SNA). This is more commonly seen in dolichocephalic breeds (a longer snout), though any breed can contract the infection. Symptoms of SNA include lack of appetite, infection symptoms (inflammation, pain, fever, etc.), lethargy, nasal discharge, and excessive sneezing. When diagnosing aspergillosis, imaging techniques, an internal nasal exam with a scope, a nasal flush, cytologies, and cultures may be utilized. In more advanced infections, hemorrhage and necrosis are possible. After diagnosis, treatment includes administration of anti-fungal medications, most often topically due to variability in response to oral treatments (Tell et al., 2019). To achieve topical administration in a complex location, catheters may be placed in the frontal sinus with scopes or trephination (holes drilled into the skull), as seen in Figure 36. Other non-invasive techniques may be utilized as well (Sharman & Mansfield, 2012).

**Figure 36**

Image of a Dog Undergoing SNA Treatment



*Note.* This dog is under anesthesia for trephination of the frontal sinuses to provide treatment for SNA.

Image obtained from Sharman & Mansfield, 2012.

This level of aspergillosis is generally not fatal, and is commonly cured (Hertel et al., 2025).

However, SNA can destroy the nasal turbinates, which assist in disease fighting. Without turbinates, or with decreased turbinates, dogs may be at higher risk of other diseases or re-infection of aspergillosis. Additionally, SNA may develop into a more systemic infection, named disseminated aspergillosis, which is largely fatal, with few having successful treatments.

This progresses from the respiratory tract into the bloodstream and traveling around the body.

Symptoms of disseminated aspergillosis include neurological symptoms, swelling, muscle wasting, and weight loss (Taboada et al., 2018). Primarily infecting the nasal sinuses, this fungal infection is largely prevented by the defense system of the upper respiratory tract of canines.

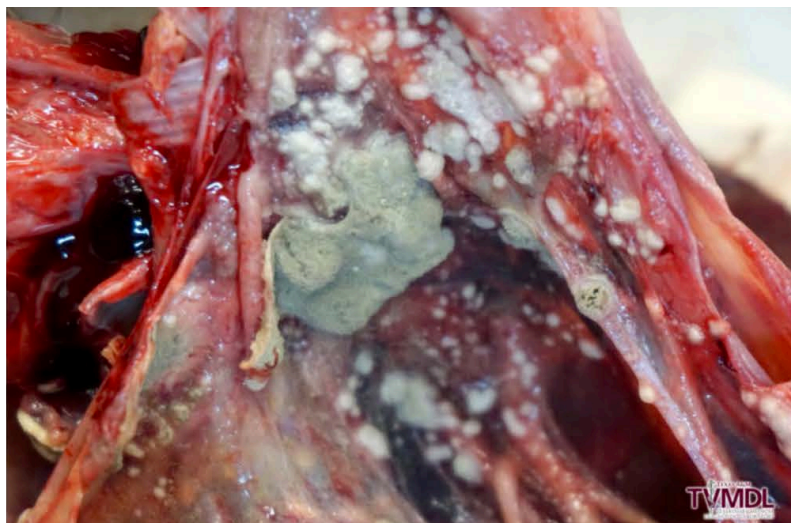
Cells that work to trap and destroy foreign particles that enter the body through respiration are found in the nasal cavity, often preventing disease like SNA ( Sharman & Mansfield, 2012).

Avian species are the most susceptible animal to aspergillosis. The reasoning behind their susceptibility is still being researched, however, the top hypotheses are regarding their air sac respiratory system, their lack of epiglottis, or their lack of a muscular diaphragm. The air sacs within the respiratory system are warm and oxygenated, with few immune cells, and little ciliated epithelium to prevent foreign materials from traveling through. The epiglottis acts as a physical barrier, and without this block, avians may be more susceptible to foreign materials in the body. Lastly, the diaphragm is utilized in inspiration and expiration in other animals, assisting in expelling particles from the lungs and airway. Without a muscular diaphragm to expel them, foreign materials may be more likely to remain in the airway (Tell et al., 2019). Symptoms in avian species include changes in activity, vocalizations, decreased appetite, balance issues, labored breathing, and weight loss. Diagnosis may include auscultation, blood work (looking for general infection signs), internal scoping, radiographs, and tracheal lavage (flush). Generally, radiographs are not successful in diagnosis unless the infection is severe. A tracheal lavage may identify inflammation, without confirmation of cause. Utilizing a scope can allow identification of granulomas that develop at areas of infection. These granulomas may be yellow, white, or tan, with varying elasticity, located on the lungs, air sacs, or other organs in systemic cases, as seen in Figure 37. Hemorrhaging and necrosis are possible developments from infection. As for treatments, it is difficult to administer a topical agent due to the site of infection often being deep within the body, and antifungals have low success rates for similar reasons. Unfortunately, the success rate for treatment in avians is low, largely due to the development of the fungus within the respiratory tract (Tell et al., 2019). With younger birds and immunodepressed birds being primary demographics for this disease, clinical signs are often seen once the disease has severely advanced (Souto et al., 2025). Within captive populations, such as rehabilitation or falconry

settings, raptors and waterfowl are extremely susceptible, due to environmental, husbandry, and stress based immunodeficiencies (Tell et al., 2019).

### **Figure 37**

Image of Aspergillosis Growth in Air Sacs



*Note.* Fungal growths of aspergillosis in avian air sacs. Image obtained from Edwards & Paul, 2024.

### ***Avian Influenza Infection***

Avian influenza, more commonly known as bird flu, is an influenza A virus. There are four antigenic types: A, B, C, and D. Influenza A infects humans and many animal species. Influenza B viruses generally only infect humans, with a few aquatic outbreaks. Influenza C infects humans, dogs, pigs, and camels, however, they are more mild infections compared to A and B types. Lastly, influenza D has been isolated from pigs and cows, with no known human infections (Mishin et al., 2019). For an influenza virus to be considered avian, it must have a bird species as its natural host. Therefore, avian influenza is not a specific strain, rather a subcategory of influenza A viruses. The virus is spread through inhalation of viral particles, which are often shed within the trachea. It can also be spread via the fecal-oral route, as viral particles are shed in feces as well. Waterfowl are common hosts for this virus due to feces in the water, spreading the

virus as they migrate and enter new geographical locations (Wahlgren, 2011). Between the two species, avian influenza presents similarly, with varying levels of severity as the disease mutates.

As a primarily avian virus, this section will begin with information on the disease in avians before moving to canine infection. Avian influenza is highly contagious with varying levels of pathogenicity. In fact, each pathogenicity is distinct. Low pathogenic avian influenza (LPAI) is generally a mild disease, causing mild respiratory sickness. Symptoms in avian species include respiratory distress, subdued behavior, infection, and decreased egg production. These symptoms are very broad, and can be the result of many other illnesses, creating difficulties in accurately diagnosing a bird with LPAI. For a formal diagnosis, serological and virological testing is required, often done via tracheal, oropharyngeal, or cloacal swabs. Additionally, once a diagnosis is made, there is no known effective treatment. Supportive therapies and anti-viral medications are the standard for care after diagnosis. Despite there being no treatment, LPAI typically does not kill birds, but it may have lasting impacts on the nervous system. In contrast, highly pathogenic avian influenza (HPAI) is nearly 100% fatal. HPAI is a mutated form of LPAI, largely increasing the pathogenicity (Ayuti et al., 2024). HPAI has caused deaths of millions of birds, impacting a range of birds from chickens to penguins (Calle-Hernandez et al., 2023).

### Figure 38

Image of a bald eagle displaying HPAI signs



*Note.* Subdued bald eagle, a sign of HPAI. Image obtained from Alaska Raptor Center, 2019.

Canine breeds are susceptible to avian influenza, with several studies showing susceptibility to H5N1 (Chen et al., 2010; Maas et al., 2007). There have been several cases of different avian influenza strains infecting dogs, including one case of a dog eating a duck infected with H5N1, who died shortly after. Despite avian influenza's ability to infect dogs, there are two strains of canine influenza as well. Originating as avian influenza H3N8, this strain infected racing greyhounds in Florida in 2004, later mutating and establishing a lineage in canines. Additionally, canine influenza H3N2 emerged in dogs in Chicago in 2015 that is consistent with the H3N2 virus in dogs in South Korea and China (Watson et al., 2016). Symptoms of influenza in canines include respiratory distress, nasal and ocular discharge, fever, infection, lethargy, and anorexia. Diagnosis of influenza virus requires serology testing, often done by isolating the virus or utilizing modified PCR tests (Anderson et al., 2022). Similar to birds, there is no effective treatment, so patients are provided with support therapies and broad antibiotics to treat and prevent secondary illnesses (Dubovi, 2010). Despite canine strains of influenza existing, the mortality rate for infected dogs ranges from 1-10%, much lower than that of HPAI (Livestock Poultry Health, 2025). In both canine and avian species, influenza is difficult to diagnose, with no treatment or vaccine available for either species. Generally, both species can recover from influenza, however, mutations can decrease survival odds and increase contagion levels.

### **Conclusion**

Comparing canine and avian skeletal and respiratory systems directly facilitates understanding of how form follows function. In terrestrial quadrupeds like canines, flexibility of the skeleton and bidirectional respiration allow maneuverability on land and effective gas exchange. To maintain flight, a large functional divergence between canine and avian species,

there are many evolutionary modifications and variations including skeletal fusions and rigidity, pneumatic bones, rigid lungs with air sacs as ventilation, and modified thoracic limbs that form the wings. Understanding these anatomical divergences facilitates the understanding of how these systems come together in fractures, such as canine flail chest or avian compounded pneumatic bones. Additionally, the variation in severity of respiratory diseases discussed can be linked to respiratory environment differences, along with structural differences.

Ultimately, despite their major differences in skeletal and respiratory structure, canines and avians share similarities both in function and pathologies. This basis of knowledge and comparison can branch to future species and pathology comparisons.

## References

- Abako, J., Holak, P., Głodek, J., & Zhalniarovich, Y. (2021). Usefulness of imaging techniques in the diagnosis of selected injuries and lesions of the canine tarsus. A review. *Animals*, *11*(6), 1834. <https://doi.org/10.3390/ani11061834>
- Ahani, S., Alizadeh, S., & Hosseinchi, M. R. (2024). Radiological and anatomical features of the skull bones of adult husky dogs. *doaj.org*. <https://doi.org/10.22067/ijvst.2024.82573.1255>
- Ahn, S., Jeong, S., & Yoon, H. (2016). Repair of flail chest using interfragmentary wiring and stability augmentation with basket-weave fashion sutures in a toy breed dog: a case report. *Veterinárni Medicína*, *61*(6), 348–352. <https://doi.org/10.17221/33/2016-vetmed>
- Aires, A. S., Reichert, L. M., Müller, R. T., & Andrade, M. B. (2021). Review of morphology, development, and evolution of the notarium in birds. *The Anatomical Record*, *305*(9), 2079–2098. <https://doi.org/10.1002/ar.24852>
- Alfonso-Carrillo, C., Benavides-Reyes, C., De Los Mozos, J., Dominguez-Gasca, N., Sanchez-Rodríguez, E., Garcia-Ruiz, A. I., & Rodriguez-Navarro, A. B. (2021). Relationship between Bone Quality, Egg Production and Eggshell Quality in Laying Hens at the End of an Extended Production Cycle (105 Weeks). *Animals*, *11*(3), 623. <https://doi.org/10.3390/ani11030623>
- Al-Janabi, S. M., & Al-jebori, J. G. A. (2025). A review on local Iraqi dog skull anatomy and radiology of regional bone. *SAR Journal of Anatomy and Physiology*, *6*(1), 20–23. <https://doi.org/10.36346/sarjap.2025.v06i01.004>
- Anderson, T. C., Crawford, P. C., Katz, J. M., Dubovi, E. J., Landolt, G., & Gibbs, E. P. J. (2012). Diagnostic performance of the canine Influenza A Virus subtype H3N8

- hemagglutination inhibition assay. *Journal of Veterinary Diagnostic Investigation*, 24(3), 499–508. <https://doi.org/10.1177/1040638712440992>
- Anthwal, N., Joshi, L., & Tucker, A. S. (2012). Evolution of the mammalian middle ear and jaw: adaptations and novel structures. *Journal of Anatomy*, 222(1), 147–160. <https://doi.org/10.1111/j.1469-7580.2012.01526.x>
- Aspergillosis in a Pacific eider - Texas A&M Veterinary Medical Diagnostic Laboratory*. (2024, August 29). Texas A&M Veterinary Medical Diagnostic Laboratory. <https://tvmdl.tamu.edu/case-studies/aspergillosis-in-a-pacific-eider/>
- O'Malley, B. (2005). Avian anatomy and physiology. In *Clinical Anatomy and Physiology of Exotic Species* (pp. 97–161). <https://doi.org/10.1016/b978-070202782-6.50009-0>
- Baliga, V. B., Szabo, I., & Altshuler, D. L. (2019). Range of motion in the avian wing is strongly associated with flight behavior and body mass. *Science Advances*, 5(10), eaaw6670. <https://doi.org/10.1126/sciadv.aaw6670>
- Beernaert, L. A., Pasmans, F., Van Waeyenberghe, L., Haesebrouck, F., & Martel, A. (2010). Aspergillus infections in birds: a review. *Avian Pathology*, 39(5), 325–331. <https://doi.org/10.1080/03079457.2010.506210>
- Berger, A. J. (1956). Anatomical variation and avian anatomy. *Ornithological Applications*, 58(6), 433–441. <https://doi.org/10.2307/1365098>
- Biewener, A. A. (2011). Muscle function in avian flight: achieving power and control. *Philosophical Transactions of the Royal Society B Biological Sciences*, 366(1570), 1496–1506. <https://doi.org/10.1098/rstb.2010.0353>

- Bigham-Sadegh, A., & Oryan, A. (2014). Basic concepts regarding fracture healing and the current options and future directions in managing bone fractures. *International Wound Journal*, *12*(3), 238–247. <https://doi.org/10.1111/iwj.12231>
- Bognár, Z., Szabó, D., Deés, A., & Kubinyi, E. (2021). Shorter headed dogs, visually cooperative breeds, younger and playful dogs form eye contact faster with an unfamiliar human. *Scientific Reports*, *11*(1). <https://doi.org/10.1038/s41598-021-88702-w>
- Botelho, J. F., Smith-Paredes, D., Nuñez-Leon, D., Soto-Acuña, S., & Vargas, A. O. (2014). The developmental origin of zygodactyl feet and its possible loss in the evolution of Passeriformes. *Proceedings of the Royal Society B Biological Sciences*, *281*(1788), 20140765. <https://doi.org/10.1098/rspb.2014.0765>
- Bueno, I., Redig, P. T., & Rendahl, A. K. (2015). External skeletal fixator intramedullary pin tie-in for the repair of tibiotarsal fractures in raptors: 37 cases (1995–2011). *Journal of the American Veterinary Medical Association*, *247*(10), 1154–1160. <https://doi.org/10.2460/javma.247.10.1154>
- Bui, H. N., & Larsson, H. C. E. (2020). Development and evolution of regionalization within the avian axial column. *Zoological Journal of the Linnean Society*, *191*(1), 302–321. <https://doi.org/10.1093/zoolinnea/zlaa038>
- Burton, M. G. P., Benson, R. B. J., & Field, D. J. (2023). Direct quantification of skeletal pneumaticity illuminates ecological drivers of a key avian trait. *Proceedings of the Royal Society B: Biological Sciences*, *290*(2995). <https://doi.org/10.1098/rspb.2023.0160>
- Calle-Hernández, D. M., Hoyos-Salazar, V., & Bonilla-Aldana, D. K. (2022). Prevalence of the H5N8 influenza virus in birds: Systematic review with meta-analysis. *Travel Medicine and Infectious Disease*, *51*, 102490. <https://doi.org/10.1016/j.tmaid.2022.102490>

*Canine influenza* | Public | Clemson University, South Carolina. (2025, December 3).

<https://www.clemson.edu/public/lph/ahp/reportable-diseases/companion-disease/canine-influenza.html>

Chen, Y., Zhong, G., Wang, G., Deng, G., Li, Y., Shi, J., Zhang, Z., Guan, Y., Jiang, Y., Bu, Z., Kawaoka, Y., & Chen, H. (2010). Dogs are highly susceptible to H5N1 avian influenza virus. *Virology*, *405*(1), 15–19. <https://doi.org/10.1016/j.virol.2010.05.024>

*Chicken feet*. (n.d.). Illinois Extension. <https://extension.illinois.edu/chicken-feeet>

Chiwitt, C. L. H., Baines, S. J., Mahoney, P., Tanner, A., Heinrich, C. L., Rhodes, M., & Featherstone, H. J. (2016). Ocular biometry by computed tomography in different dog breeds. *Veterinary Ophthalmology*, *20*(5), 411–419. <https://doi.org/10.1111/vop.12441>

Codd, J. R. (2009). Uncinate processes in birds: Morphology, physiology and function.

*Comparative Biochemistry and Physiology Part a Molecular & Integrative Physiology*, *156*(3), 303–308. <https://doi.org/10.1016/j.cbpa.2009.12.005>

Coutant, T., Lair, S., Fitzgerald, G., Perret-Thiry, C., & Vergneau-Grosset, C. (2022). Risk Factors and Prognosis for Humeral Fractures in Birds of Prey: A Retrospective Study of 461 Cases from 2000 to 2015. *Journal of Avian Medicine and Surgery*, *36*(1), 2–13. <https://doi.org/10.1647/20-00093>

De Troyer, A., & Wilson, T. A. (2000). The canine parasternal and external intercostal muscles drive the ribs differently. *The Journal of Physiology*, *523*(3), 799–806.

<https://doi.org/10.1111/j.1469-7793.2000.00799.x>

Deban, S. M., Schilling, N., & Carrier, D. R. (2011). Activity of extrinsic limb muscles in dogs at walk, trot and gallop. *Journal of Experimental Biology*, *215*(2), 287–300.

<https://doi.org/10.1242/jeb.063230>

- Dyce, K. M., Sack, W. O., & Wensing, C. J. G. (2009). *Textbook of Veterinary Anatomy - E-Book*. Elsevier Health Sciences.
- Espinosa, J., Guijarro, J., Zapico, D., Criado, M., Del Carmen Ferreras, M., & Pérez, V. (2025). Histologic characterization of fracture repair process in wild birds in association with gross appearance of the bone lesion. *Veterinary Pathology*, *62*(5), 781–792.  
<https://doi.org/10.1177/03009858251317458>
- Ewart, S. L. (2020). Overview of respiratory function: ventilation of the lungs. In *Elsevier eBooks* (pp. 518–531). <https://doi.org/10.1016/b978-0-323-55227-1.00045-4>
- Fedde. (1998). Relationship of structure and function of the avian respiratory system to disease susceptibility. *Poultry Science*, *77*(8), 1130–1138. <https://doi.org/10.1093/ps/77.8.1130>
- Felice, R. N. (2014). Coevolution of caudal skeleton and tail feathers in birds. *Journal of Morphology*, *275*(12), 1431–1440. <https://doi.org/10.1002/jmor.20321>
- Filardi, V. (2019). Healing of tibial comminuted fractures by the meaning of an innovative intramedullary nail. *Journal of Orthopaedics*, *16*(2), 145–150.  
<https://doi.org/10.1016/j.jor.2019.02.026>
- Fish, F. E., Sheehan, M. J., Adams, D. S., Tennett, K. A., & Gough, W. T. (2020). A 60:40 split: Differential mass support in dogs. *The Anatomical Record*, *304*(1), 78–89.  
<https://doi.org/10.1002/ar.24407>
- Gartrell, B., Alley, & Kelly, T. (2003). Bacterial sinusitis as a cause of beak deformity in an Antipodes Island parakeet(*Cyanoramphus unicolor*). *New Zealand Veterinary Journal*, *51*(4), 196–198. <https://doi.org/10.1080/00480169.2003.36365>

- Georgevsky, D., Carrasco, J. J., Valenzuela, M., & McGreevy, P. D. (2014). Domestic dog skull diversity across breeds, breed groupings, and genetic clusters. *Journal of Veterinary Behavior*, 9(5), 228–234. <https://doi.org/10.1016/j.jveb.2014.04.007>
- González, M. S. (2019). Skeletal bone structure and repair in small mammals, birds, and reptiles. *Veterinary Clinics of North America Exotic Animal Practice*, 22(2), 135–147. <https://doi.org/10.1016/j.cvex.2019.01.002>
- Gusseklou, S. W. S., & Bout, R. G. (2005). Cranial kinesis in palaeognathous birds. *Journal of Experimental Biology*, 208(17), 3409–3419. <https://doi.org/10.1242/jeb.01768>
- Hall, M. I. (2008). The anatomical relationships between the avian eye, orbit and sclerotic ring: implications for inferring activity patterns in extinct birds. *Journal of Anatomy*, 212(6), 781–794. <https://doi.org/10.1111/j.1469-7580.2008.00897.x>
- Hall, M. I., & Ross, C. F. (2006). Eye shape and activity pattern in birds. *Journal of Zoology*, 271(4), 437–444. <https://doi.org/10.1111/j.1469-7998.2006.00227.x>
- Harvey, E. P., & Ben-Tal, A. (2016). Robust Unidirectional Airflow through Avian Lungs: New Insights from a Piecewise Linear Mathematical Model. *PLoS Computational Biology*, 12(2), e1004637. <https://doi.org/10.1371/journal.pcbi.1004637>
- Hertel, F., & Campbell, K. E. (2007). The Antitrochanter of birds: form and function in balance. *The Auk*, 124(3), 789–805. <https://doi.org/10.1093/auk/124.3.789>
- Hieronimus, T. L. (2016). Flight feather attachment in rock pigeons (*Columba livia*): covert feathers and smooth muscle coordinate a morphing wing. *Journal of Anatomy*, 229(5), 631–656. <https://doi.org/10.1111/joa.12511>
- Highly pathogenic avian influenza – Alaska Raptor Center*. (n.d.). <https://alaskaraptor.org/hpai/>

- Höfling, E., & Abourachid, A. (2020). The skin of birds' feet: Morphological adaptations of the plantar surface. *Journal of Morphology*, 282(1), 88–97.  
<https://doi.org/10.1002/jmor.21284>
- Holz, P. (2003). Coracoid fractures in wild birds: repair and outcomes. *Australian Veterinary Journal*, 81(8), 469–471. <https://doi.org/10.1111/j.1751-0813.2003.tb13362.x>
- Huang, K., Xu, Z., Sun, J., Ding, X., Wu, B., Li, W., Qin, X., & Tang, H. (2014). Stabilization of multiple rib fractures in a canine model. *Journal of Surgical Research*, 192(2), 621–627.  
<https://doi.org/10.1016/j.jss.2014.07.052>
- Hui, C. A. (2001). Avian furcula morphology may indicate relationships of flight requirements among birds. *Journal of Morphology*, 251(3), 284–293. <https://doi.org/10.1002/jmor.1089>
- Hummel, E., Ozel, M., Medina-Jerez, W., Fančovičová, J., Usak, M., Prokop, P., & Randler, C. (2015). Interest in Birds and its Relationship with Attitudes and Myths: A Cross-cultural Study in Countries with Different Levels of Economic Development. *Educational Sciences Theory & Practice*. <https://doi.org/10.12738/estp.2015.1.2242>
- Jacob, J., Pescatore, T., & University of Kentucky College of Agriculture, Food and Environment. (2013). Avian Skeletal System. In *University of Kentucky College of Agriculture, Food and Environment*.  
<https://www2.ca.uky.edu/agcomm/pubs/ASC/ASC202/ASC202.pdf>
- Jain, R., Shukla, B. P., Nema, S., Skukla, S., Chabra, D., & Karmore, S. K. (2018). Incidence of fracture in dog: a retrospective study. *Veterinary Practitioner*, 19(1), 63–65.
- Johns Hopkins. (n.d.). *Fractures*. Johns Hopkins Medicine.  
<https://www.hopkinsmedicine.org/health/conditions-and-diseases/fractures>

- Kassem, M. A. M., Tahon, R. R., & El-Ayat, M. A. (2024). Anatomical and morphometric studies on the axial skeleton of ostrich (*Struthio camelus*). *Zoomorphology*, *143*(1), 231–248. <https://doi.org/10.1007/s00435-024-00642-x>
- Kayıkcı, C., Kuşcu, Y., Durmuş, A., & Aslan, L. (2019, July 26). *Fractures and treatment methods in wild avians*. <https://dergipark.org.tr/en/pub/vanvetj/issue/47335/548491>
- Keir, J. (2008). Why do we have paranasal sinuses? *The Journal of Laryngology & Otology*, *123*(1), 4–8. <https://doi.org/10.1017/s0022215108003976>
- Lee, S., Kim, J., Park, H., Jabłoński, P. G., & Choi, H. (2015). The function of the Alula in avian flight. *Scientific Reports*, *5*(1), 9914. <https://doi.org/10.1038/srep09914>
- Li, Z., Zhu, W., Zhang, B., Zhang, Y., Li, H., Lv, B., Zhen, Q., Liu, L., Liu, L., Wu, Y., & Li, S. (2023). A novel minimally invasive fixation method for flail chest management in a Canine model: an animal research. *Journal of Cardiothoracic Surgery*, *18*(1), 359. <https://doi.org/10.1186/s13019-023-02445-5>
- Liu, N.-C., Troconis, E. L., Kalmar, L., Price, D. J., Wright, H. E., Adams, V. J., Sargan, D. R., & Ladlow, J. F. (2017). Conformational risk factors of brachycephalic Obstructive airway Syndrome (BOAS) in pugs, French bulldogs, and bulldogs. *PloS One*, *12*(8), e0181928. <https://doi.org/10.1371/journal.pone.0181928>
- Maas, R., Tacke, M., Ruuls, L., Koch, G., Van Rooij, E., & Stockhofe-Zurwieden, N. (2007). Avian influenza (H5N1) susceptibility and receptors in dogs. *Emerging Infectious Diseases*, *13*(8), 1219–1221. <https://doi.org/10.3201/eid1308.070393>
- Maina, J. N. (2007). Development, structure, and function of a novel respiratory organ, the lung-air sac system of birds: to go where no other vertebrate has gone. *Biological*

*Reviews/Biological Reviews of the Cambridge Philosophical Society*, 81(4), 545–579.

<https://doi.org/10.1111/j.1469-185x.2006.tb00218.x>

Maina, J. N. (2022). Perspectives on the structure and function of the Avian Respiratory System: functional efficiency built on structural complexity. *Frontiers in Animal Science*, 3.

<https://doi.org/10.3389/fanim.2022.851574>

Maina, J. N. (2025). Structure and function of the avian respiratory system. *Philosophical Transactions of the Royal Society B Biological Sciences*, 380(1920), 20230435.

<https://doi.org/10.1098/rstb.2023.0435>

Marek, R. D. (2023). A surrogate forelimb: Evolution, function and development of the avian cervical spine. *Journal of Morphology*, 284(10), e21638.

<https://doi.org/10.1002/jmor.21638>

Marsell, R., & Einhorn, T. A. (2011). The biology of fracture healing. *Injury*, 42(6), 551–555.

<https://doi.org/10.1016/j.injury.2011.03.031>

Marugán-Lobón, J., Nebreda, S. M., Navalón, G., & Benson, R. B. J. (2021). Beyond the beak: Brain size and allometry in avian craniofacial evolution. *Journal of Anatomy*, 240(2),

197–209. <https://doi.org/10.1111/joa.13555>

Masoudifard, M., Zehtabvar, O., Shahbazi, A., Raad, S. B., & Tonekabony, S. H. M. (2025). Anatomical Study of the Scleral Ring and Scleral Ossicles of the Ostrich (*Struthio camelus*) With Gross Anatomical Methods and Diagnostic Imaging Techniques.

*Veterinary Medicine International*, 2025(1), 4993179.

<https://doi.org/10.1155/vmi/4993179>

- McCarthy, P. H., & Wood, A. K. (1988). Anatomic and radiologic observations of the clavicle of adult dogs. *American Journal of Veterinary Research*, *49*(6), 956–959.  
<https://pubmed.ncbi.nlm.nih.gov/3400932/>
- Moore, A. J., & Schachner, E. R. (2025). When the lung invades: a review of avian postcranial skeletal pneumaticity. *Philosophical Transactions of the Royal Society B Biological Sciences*, *380*(1920), rstb20230427. <https://doi.org/10.1098/rstb.2023.0427>
- Nascimento, B. M., Giovanelli, D. F., Dissenha, A., Quessada, A. M., Boscarato, A. G., & Bellettini, S. T. (2024). Appendicular skeleton fractures in dogs. *Concilium*, *24*(18), 38–57. <https://doi.org/10.53660/clm-4072-24s04>
- Petevinos, H. (2006). A Method for Resolving Subcutaneous Emphysema in a Griffon Vulture Chick (*Gyps fulvus*). *Journal of Exotic Pet Medicine*, *15*(2), 132–137.  
<https://doi.org/10.1053/j.jepm.2006.02.009>
- Pozzi, A., Lewis, D. D., Scheuermann, L. M., Castelli, E., & Longo, F. (2021). A review of minimally invasive fracture stabilization in dogs and cats. *Veterinary Surgery*, *50*(S1), O5–O16. <https://doi.org/10.1111/vsu.13685>
- Rayner, J. M. V. (1988). Form and Function in Avian Flight. In *Current Ornithology* (pp. 1–66).  
[https://doi.org/10.1007/978-1-4615-6787-5\\_1](https://doi.org/10.1007/978-1-4615-6787-5_1)
- Regnault, S., Pitsillides, A. A., & Hutchinson, J. R. (2014). Structure, ontogeny and evolution of the patellar tendon in emus (*Dromaius novaehollandiae*) and other palaeognath birds. *PeerJ*, *2*, e711. <https://doi.org/10.7717/peerj.711>
- Schaub, K. I., Kelleners, N., Schmidt, M. J., Eley, N., & Fischer, M. S. (2021). Three-Dimensional kinematics of the pelvis and caudal lumbar spine in German shepherd

- dogs. *Frontiers in Veterinary Science*, 8, 709966.  
<https://doi.org/10.3389/fvets.2021.709966>
- Scheelings, T. F. (2014). Coracoid fractures in wild birds: A comparison of surgical repair versus conservative treatment. *Journal of Avian Medicine and Surgery*, 28(4), 304–308.  
<https://doi.org/10.1647/2013-038>
- Schmidt-Nielsen, K. (1971). How birds breathe. *Scientific American*, 225(6), 72–79.
- Seki, R., Kamiyama, N., Tadokoro, A., Nomura, N., Tsuihiji, T., Manabe, M., & Tamura, K. (2012). Evolutionary and developmental aspects of Avian-Specific traits in limb skeletal pattern. *ZOOLOGICAL SCIENCE*, 29(10), 631–644. <https://doi.org/10.2108/zsj.29.631>
- Sharman, M. J., & Mansfield, C. S. (2012). Sinonasal aspergillosis in dogs: a review. *Journal of Small Animal Practice*, 53(8), 434–444.  
<https://doi.org/10.1111/j.1748-5827.2012.01245.x>
- Sop, J. L., & Sop, A. (2023, August 8). *Open Fracture Management*. StatPearls - NCBI Bookshelf. <https://www.ncbi.nlm.nih.gov/books/NBK448083/>
- Souto, E., Garcia, D., Santos, C., Batista, J., Kommers, G., Galiza, G., Mota, R., & Dantas, A. (2025). Aspergillosis in domestic and wild birds in northeastern Brazil: 2000-2022. *Arquivo Brasileiro De Medicina Veterinária E Zootecnia*, 77(3).  
<https://doi.org/10.1590/1678-4162-13317>
- Swayne, D. E., & Suarez, D. L. (2000). Highly pathogenic avian influenza. *Revue Scientifique Et Technique De L' OIE*, 19(2), 463–482. <https://doi.org/10.20506/rst.19.2.1230>
- Tell, L. A., Burco, J. D., Woods, L., & Clemons, K. V. (2019). Aspergillosis in birds and mammals: Considerations for veterinary medicine. In *Fungal biology* (pp. 49–72).  
[https://doi.org/10.1007/978-3-030-18586-2\\_4](https://doi.org/10.1007/978-3-030-18586-2_4)

- Thøfner, I., Hougen, H. P., Villa, C., Lynnerup, N., & Christensen, J. P. (2020). Pathological characterization of keel bone fractures in laying hens does not support external trauma as the underlying cause. *PLoS ONE*, *15*(3), e0229735.  
<https://doi.org/10.1371/journal.pone.0229735>
- Travlos, G. S. (2006). Normal structure, function, and histology of the bone marrow. *Toxicologic Pathology*, *34*(5), 548–565. <https://doi.org/10.1080/01926230600939856>
- Tully, T. N. (2002). Basic avian bone growth and healing. *Veterinary Clinics of North America Exotic Animal Practice*, *5*(1), 23–30. [https://doi.org/10.1016/s1094-9194\(03\)00044-6](https://doi.org/10.1016/s1094-9194(03)00044-6)
- Van Den Broek, D. H. N., Vester, S. C., Restrepo, M. T., & Veraa, S. (2023). Sternal abnormalities on thoracic radiographs of dogs and cats. *Animals*, *13*(7), 1233.  
<https://doi.org/10.3390/ani13071233>
- Vazquez, R. J. (1995). Functional anatomy of the pigeon hand (*Columba livia*): A muscle stimulation study. *Journal of Morphology*, *226*(1), 33–45.  
<https://doi.org/10.1002/jmor.1052260104>
- Vergneau-Grosset, C., Kapatkin, A. S., Paul-Murphy, J., Guzman, D. S., & Hawkins, M. G. (2019). Release rates and complications for birds of prey with antebrachial fractures at a veterinary teaching hospital. *Journal of Avian Medicine and Surgery*, *33*(4), 388.  
<https://doi.org/10.1647/2018-394>
- Walter, R. M., & Carrier, D. R. (2007). Ground forces applied by galloping dogs. *Journal of Experimental Biology*, *210*(2), 208–216. <https://doi.org/10.1242/jeb.02645>
- Wilken, A. T., Middleton, K. M., Sellers, K. C., Cost, I. N., & Holliday, C. M. (2019). The roles of joint tissues and jaw muscles in palatal biomechanics of the Savannah monitor

- (*Varanus exanthematicus*) and their significance for cranial kinesis. *Journal of Experimental Biology*, 222(Pt 18). <https://doi.org/10.1242/jeb.201459>
- Williams, J. (2002). Orthopedic radiography in exotic animal practice. *Veterinary Clinics of North America Exotic Animal Practice*, 5(1), 1–22.  
[https://doi.org/10.1016/s1094-9194\(03\)00043-4](https://doi.org/10.1016/s1094-9194(03)00043-4)
- Williams, S. B., Wilson, A. M., Daynes, J., Peckham, K., & Payne, R. C. (2008). Functional anatomy and muscle moment arms of the thoracic limb of an elite sprinting athlete: the racing greyhound (*Canis familiaris*). *Journal of Anatomy*, 213(4), 373–382.  
<https://doi.org/10.1111/j.1469-7580.2008.00962.x>
- Wu, Q., O'Connor, J. K., Wang, S., & Zhou, Z. (2024). Transformation of the pectoral girdle in pennaraptorans: critical steps in the formation of the modern avian shoulder joint. *PeerJ*, 12, e16960. <https://doi.org/10.7717/peerj.16960>
- Xu, X., & Mackem, S. (2013). Tracing the evolution of avian wing digits. *Current Biology*, 23(12), R538–R544. <https://doi.org/10.1016/j.cub.2013.04.071>
- Yalin, E. E., Altundağ, Y., Altunatmaz, K., Çakar, B., Acar, E., Pasicka, E., Özkan, E., Gündemir, O., & Spataru, M. (2025). Patellar shape variation in cats and dogs: Implications for orthopedic surgical planning. *Animals*, 15(11), 1608. <https://doi.org/10.3390/ani15111608>
- Young, M. W., Wilken, A. T., Manafzadeh, A. R., Schurr, A. F., Bastian, A., Dickinson, E., & Granatosky, M. C. (2023). The dual function of prokinesis in the feeding and locomotor systems of parrots. *Journal of Experimental Biology*, 226(24).  
<https://doi.org/10.1242/jeb.246659>

Zink, C., & Schlehr, M. R. (2020). Working dog structure: evaluation and relationship to function. *Frontiers in Veterinary Science*, 7(4971), 29–559055.

<https://doi.org/10.3389/fvets.2020.559055>