

WHAT'S INSIDE

Letter From Dr. McIlwraith.....	2
EORC Investigators Awarded AQHA Grant for Studying Stifle Disease in Quarter Horses	3
Researchers Study Effect of Temperature on Synthetic Racing Track Surfaces.....	3
Royal Veterinary College Honors Dr. McIlwraith	4
Feature Film Starring Equine Researchers Wins Award.....	4
Bioengineer Develops Wireless Sensor to Track Healing of Difficult-to-Treat Bone Fractures	5
Significant Studies Increase Information About MRI	6
Osteoarthritis: Not Just an 'Old-Horse Disease'	8
Searching for Solutions	11
Incidences of Radiographic Changes in Quarter Horse Yearlings Identified.....	13
New Graduate Students	14
2009 Equine Orthopaedic Research Center Supporters.....	15
Advisory Board 2010.....	15
Current Research Sponsors.....	15
Autologous Conditioned Serum in the Treatment of Equine Osteoarthritis.....	16

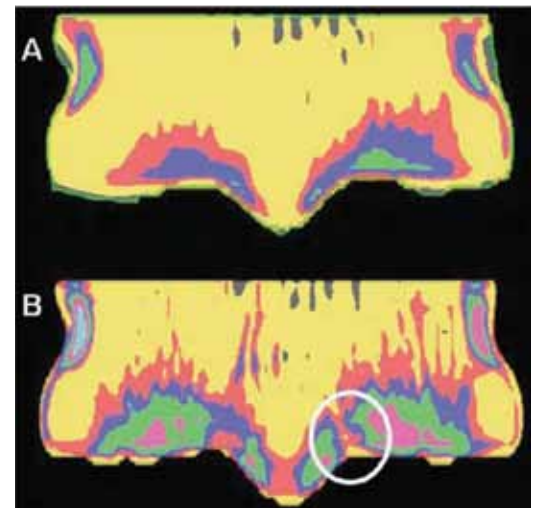
EORC Investigators Show Positive Effects of Exercise in Foals

Drs. Chris Kawcak and Wayne McIlwraith, in collaboration with Dr. Elwyn Firth from Massey University, recently published an article entitled "Effects of early exercise on metacarpophalangeal joints in horses" in the *American Journal of Veterinary Research* (Kawcak CE, McIlwraith CW, Firth E. Effects of early exercise on metacarpophalangeal joints in horses. *Am Vet J Res* 2010;71:405-411). This report was part of the Global Equine Research Alliance's study on the effects of exercise in foals.

As review, this study was performed in order to determine if early exercise could further strengthen horse limbs in order to reduce the chances of injury later in life. In this study, 12 18-month-old horses were analyzed. All of these horses had been turned out as foals; however, half of them also had an additional 1,000 meters of galloping exercise five days per week since 3 weeks of age. The horses that were exercised had fewer gross lesions in their fetlock joints and had greater bone density and greater bone formation rate compared to the nonexercised horses. The only potential negative effect was that there was slightly less cartilage matrix staining in the exercised horses, meaning that they had slightly less glycosaminoglycans in the cartilage matrix than control horses. An interesting finding here was that the bone density pattern

that leads to fracture was no different between the two groups, indicating that exercise at an early age did not predispose horses to injury. Investigators found that the exercise was safe for the young horses as none of them showed any musculoskeletal injuries during that time.

Overall, the investigators concluded that not only was exercise safe but beneficial to the bone beneath the cartilage. However, there is a concern that it may cause slight reduction in articular cartilage matrix quality which needs to be further investigated.



Images obtained from computed tomographic examination of fetlock joints indicating density patterns that are normal (A) and an image graded as severe density gradient (B) in an area predisposed to fracture. The encircled area has low density where fracture typically occurs. There was no effect of exercise on the frequency of severe density gradients in this group of foals.

Letter From Dr. McIlwraith

Welcome to the Fall 2010 edition of *Arthros*. Our newsletter highlights some of our important findings in the last year, and we also reprint two articles on Equine Osteoarthritis featuring our program: "Osteoarthritis: Not Just an 'Old Horse Disease'" and "Searching for Solutions." Both these articles were published in different issues of *The Horse*.

Further details of our research productivity for the last two years are available in our 2008-2009 Laboratory Report that was produced earlier this year. If you have not received a copy and would like one, please contact Paula Vanderlinden at the ORC.

Thanks to the ability and hard work of our faculty and staff, we continue to make progress in new imaging techniques such as CT and MRI, to validate newer biological therapies, and to be at the cutting edge of stem cell research. Challenges continue with funding in these recessionary times, and we appreciate all the support we are getting from our donors as well as research funding agencies. We will continue to justify your investment in what we do here.

Best wishes,



Wayne McIlwraith
Director



Arthros

Mailing Address:

Colorado State University
College of Veterinary Medicine and
Biomedical Sciences
Equine Orthopaedic Research
Center
Fort Collins, CO 80523-1678
Phone: (970) 297-4165
Fax: (970) 297-4118
E-mail: paula.vanderlinden@
colostate.edu
Web: www.csuequineortho.com

Gail Holmes Equine Orthopaedic Research Center

Director: Dr. Wayne McIlwraith

Editors: Wayne McIlwraith and
Paula Vanderlinden

Graphic Design: Communications
and Creative Services, Colorado
State University

*Arthros is an annual Colorado State
University Equine Orthopaedic
Research Center publication.*

Our Purpose:

To find solutions to musculoskeletal problems, especially joint injuries and arthritis in horses and humans.

Our Philosophy:

To offer the best treatment of clinical cases possible, with continued and critical assessment of our results; to use these results to change our treatments; to point our research toward prevention of problems we cannot treat effectively or that cause permanent clinical damage.

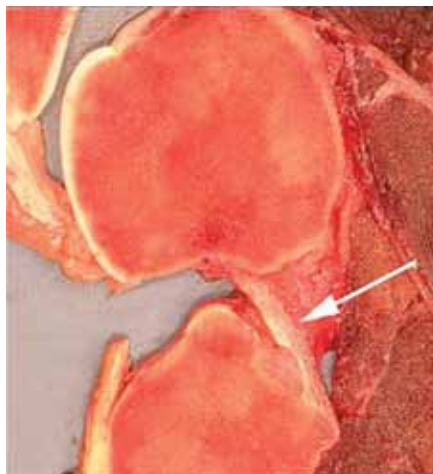
Our Goals:

To find new methods to heal joints already damaged; to use state-of-the-art research techniques to find ways to prevent the occurrence of joint diseases and musculoskeletal injuries; to find methods of early treatment to prevent permanent damage when joint disease does occur.

Visit us on the Web at
www.csuequineortho.com.

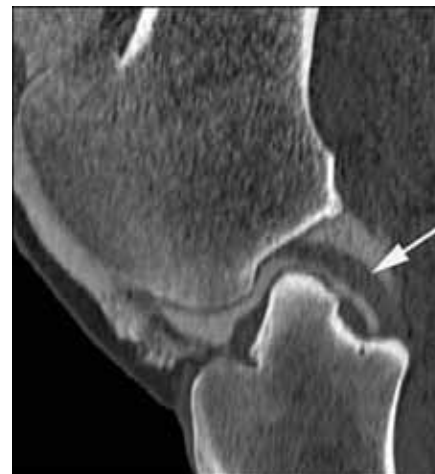EORC Investigators Awarded AQHA Grant for Studying Stifle Disease in Quarter Horses

Dr. Chris Kawcak is spearheading an investigation into a new diagnostic tool for characterizing joint disease in the stifles of Quarter Horses. Drs. Wayne McIlwraith, Laurie Goodrich, and Natasha Werpy are co-investigators on this study, which will use computed tomographic analysis to further define the injuries that occur in stifles. Stifle injury is a common problem in Quarter Horses, yet it is very difficult to fully diagnose. Unlike the knee joints in humans and dogs, veterinarians are very limited in their ability to see all of the tissues in the stifle joint. Although radiographs, ultrasound, and arthroscopic surgery are useful, the entire joint surface cannot be seen and MRI cannot be done in the live cutting or racing horse at this stage. Therefore, the investigators are



Contrast-enhanced computed tomographic image of a stifle joint showing the cruciate ligament compared to a gross image of the same joint.

now using computed tomography to gain a three-dimensional picture of the joint in order to better characterize disease. The



investigators are currently enrolling cases in the study, which should be completed at the end of 2011.

Researchers Study Effect of Temperature on Synthetic Racing Track Surfaces

Recently, two referred publications have been produced from the collaborative work between Dr. Mick Peterson, Professor of Engineering at the University of Maine, working with Dr. Wayne McIlwraith on track surface studies.

Synthetic racetracks have been introduced in a number of places in North America and have been mandated in Southern California. They have become a controversial issue due to perceptions that while decreasing catastrophic injury they can cause other problems and are subject to variability. Two studies were done on synthetic racetracks with funding from both the Grayson-Jockey Club Research Foundation as well as the Oaktree Foundation.

Techniques were developed by Dr. Peterson to evaluate the racetracks, particularly the wax within these synthetic racetracks. Pilot epidemiological data and popular perceptions had suggested that the synthetic racing surfaces degrade over time. The most likely cause of the changes over time was considered to be the wax coatings. In order to understand the composition and thermal response of wax density measurements, drop melt temperature tests, differential scanning calorimetry, and gas chromatography were used.

The project started because of a noticeable difference in training and racing times and the speed with which the horse could cover the racetrack in the morning in training compared to racing in the afternoon when the ambient temperature had increased

significantly. Five different racetracks were sampled. It became apparent that wax was undergoing varying degrees of melting and this general response was shared by all the tracks. However, there were individual differences among tracks. Changes in mechanical properties were demonstrated with increased temperature and melting of the wax. This information is being used to potentially change the types of wax used in the track as well as the development of cooling procedures, such as watering of the track to maintain it within a target temperature range.

A second study showed that six furlong race and work times had a significant correlation to track temperature. This confirmed that control of the temperature of the synthetic tracks was important for maintaining consistent performance.

Royal Veterinary College Honors Dr. McIlwraith



Dr. Wayne McIlwraith

Dr. Wayne McIlwraith, Colorado State University Distinguished Professor and Director of the Orthopaedic Research Center, recently traveled to England to receive a DVet Med (honoris causa) degree from the Royal Veterinary College, University of London on July 20, 2010.

The Royal Veterinary College is one of the world's leading specialist veterinary institutions, and it is the largest and oldest independent veterinary school in the United Kingdom. The award is the highest honor the college bestows.

Professor Quintin McKellar, Principal of the RVC, noted that the award is conferred on individuals of exceptional

academic merit who have also helped or been associated with the College in one way or another. "Clearly you fall into both categories and were therefore considered an outstanding candidate," said Professor McKellar to Dr. McIlwraith.

Dr. McIlwraith has previously received honorary doctorates from the University of Vienna in 1995, Purdue University in 2001, Massey University in New Zealand in 2003, and the University of Turin, Italy, in 2004.

Feature Film Starring Equine Researchers Wins Award

A groundbreaking film that demonstrates how animal research yields new discoveries and treatments resulting in longer, healthier lives for animals and humans has won a Telly Award.

Majestic proves the importance of translational research and shows viewers how research with animals continues to contribute to saving both human and animal lives.

Filmed on location in Kentucky, Virginia, Colorado, Missouri, and California, the award-winning *Majestic* follows the breakthrough impact that humane and responsible animal research has had on equine medicine.

The film features interviews with two of the world's leading equine surgeons and veterinarians, including Dr. Larry Bramlage (Rood & Riddle Equine Hospital) and Dr. Wayne McIlwraith



(Colorado State University), and highlights revolutionary surgical procedures, gene therapies, and animal research developments that are extending the life expectancy of horses with osteoarthritis and other joint injuries. These same procedures are often transferred to humans with degenerative joint diseases. *Majestic* was filmed and produced by the Foundation for Biomedical Research and is available for purchase, classroom use, and small group exhibition.

The Telly Awards honor outstanding local, regional, and cable TV commercials and programs, as well as the finest video and film productions and work created for the Web.

Established in 1981, the Foundation for Biomedical Research is the nation's oldest and largest organization devoted to educating the public about the essential role of humane animal research in the quest for medical advancements, treatments, and cures for both humans and animals. For more information, visit www.fbresearch.org.

Colorado State University's 12th Annual Stallion Auction to benefit Equine Research

Jan. 12-15, 2011

Online bidding opens at 11 a.m., Jan. 12, 2011, and closes at 11 a.m., Jan. 15, 2011 (all times MST).

Bid Online!

Go to www.csuequineortho.com and click on the Stallion Auction link. Bids do not include chute fees, booking fees, or associated reproductive and veterinary costs. Winning bid amounts in excess of published stud fees may be tax-deductible.

How You Are Helping

Proceeds will go to the outstanding equine research programs at Colorado State University's Orthopaedic Research Center and Equine Reproduction Laboratory. With your bid, you can help these programs improve the musculoskeletal and reproductive health of horses.

Questions? Call (970) 297-4165 or e-mail Paula.Vanderlinden@ColoState.edu. Stallions and minimum bids listed at www.csuequineortho.com.



Bioengineer Develops Wireless Sensor to Track Healing of Difficult-to-Treat Bone Fractures

Christian Puttlitz, Associate Professor of Mechanical Engineering and a faculty member in the School of Biomedical Engineering, is providing physicians with the tools they need to determine if early healing is occurring properly in difficult to treat bone fractures.

Making Sure Bone Is Healing Properly

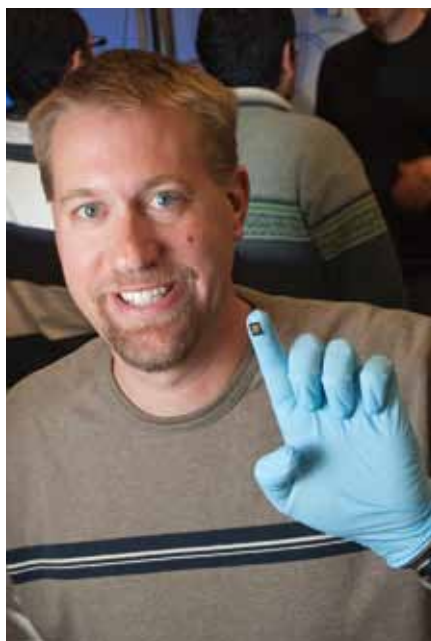Physicians treat more than 6 million bone fractures in the United States every year and about 10 percent of these fractures don't heal properly. Multifragmentary or "comminuted" fractures, where the bone splits in several pieces, are especially difficult to treat and often require the implantation of screws and a plate to stabilize the healing bone.

During the early healing phase, the plate and screws protect the fracture site by taking on most of the loading at the site. As time goes on, the healing tissue starts to share more of the load.

The first three months is a critical time period when physicians closely monitor the patient to make sure the bone is healing properly. However, conventional X-rays cannot discriminate whether this is actually occurring.

Wireless Monitoring System

Dr. Puttlitz is providing physicians with the tools they need to determine if early healing is occurring properly. Dr. Puttlitz came to Colorado State University in 2005 after working as a professor at the University of California, San Francisco, while directing a biomechanics laboratory at San Francisco General Hospital. It was his experience at SFGH that motivated Dr. Puttlitz to try to design a wireless fracture monitoring system that ultimately would lead to better patient outcomes.



Dr. Christian Puttlitz, Associate Professor of Mechanical Engineering, shows the new wireless sensor he has developed to assess whether bone is healing correctly.

"My mission as a bioengineer is to have a positive impact on human health," says Dr. Puttlitz. "If we can develop this technology to the point where patients with difficult fractures experience less pain and have fewer long-term complications, then I think we will have fulfilled this goal."

More Precise Technique, Better Patient Outcomes

Students work with Dr. Puttlitz on specimen preparation for biomechanical testing of human tissue in the Orthopaedic Bioengineering Research Laboratory at Colorado State.

Dr. Puttlitz and his collaborators have developed a new sensor that uses the changes in the load sharing between the implanted plate and healing tissue to assess whether the bone is healing correctly.

"The wireless sensor that we're developing will provide physicians with a more precise technique to assess how the healing in complicated fractures is progressing," says Dr. Puttlitz.

"By engineering newer designs, we have been able to optimize the sensor's sensitivity and fully characterize its response to different forces."

\$900,000 NIH Grant

A three-year, \$900,000 grant from the National Institutes of Health was recently awarded to Dr. Puttlitz, principal investigator on the project, and Hilmi Volkan Demir, a physics and electrical engineering professor at Bilkent University in Ankara, Turkey. The investigative team also includes experts in human and veterinary orthopedic surgery. This grant enables them to continue exploring biomedical engineering applications of wireless radio-frequency microelectromechanical systems strain sensors.

As part of this novel study, they are developing and testing the use of telemetric sensors that have been shown to be a vast improvement over traditional radio-frequency structures.

Ready to Start Designing Studies for Human Use

"Our laboratory data indicate that we can achieve the maximum level of sensitivity and accuracy across a broad range of frequencies," notes Dr. Puttlitz. "We are ready to start designing studies for human use."

Originally published in the College of Engineering Healing Health newsletter, Spring 2010.

Significant Studies Increase Information About MRI

Positive Contrast Magnetic Resonance Bursography to Determine the Presence of Pathologic Change in the Navicular Bursa and Surrounding Soft Tissue Structures

Foot pain in horses is a common source of lameness and can be caused by many different injuries. The prognosis in these cases is dependent on the severity of injury and the structures involved. Injury to the deep digital flexor tendon and surrounding structures such as the distal sesamoidean impar ligament, collateral sesamoidean ligament, and navicular bone, as well as adhesions between these structures, are a potential cause of palmar heel pain. Adhesions carry a poor to grave prognosis for return to soundness.

The navicular bursa, a fluid-filled sac, is located between the navicular bone and the deep digital flexor tendon. Adhesions can develop in the navicular bursa from location inflammation and when there is injury to the deep digital flexor tendon and/or the navicular bone. Magnetic resonance imaging is considered the modality of choice for diagnosis of soft tissue injury and is commonly used to determine the cause of lameness in the foot. However, the ability to detect adhesions in the foot on MR images is impacted by the anatomy and the close proximity of the soft tissue structures. The interface between the DDFT and the navicular bone flexor surface can be difficult to visualize, especially when there is minimal fluid in the navicular bursa.

Adhesions are suspected on MR images when the normal fluid in the navicular bursa separating the DDFT from the navicular bone cannot be identified. The presence of adhesions are also suspected when abnormalities are identified in the navicular bone flexor surface. However, tissue proliferation in the navicular bursa adjacent to surrounding structures can be difficult to differentiate from adhesion formation between structures.

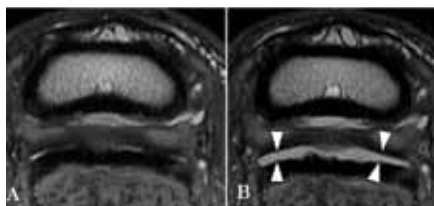


Figure 1: Transverse images pre (A) and post (B) distension of the navicular bursa. A) The dorsal margin of the DDFT has diffuse abnormalities. In multiple areas, fluid cannot be identified dorsal to the deep digital flexor tendon. These findings are suspicious of adhesions to the DDFT. B) Following distension the DDFT is completely separated from the CSL by fluid in the navicular bursa, indicating no adhesions between these structures. Arrowheads indicate fluid distension of the bursa.

This study utilized contrast to distend the navicular bursa and further delineate possible causes of foot pain on MR images. Contrast was placed in the navicular bursa using the same needle-guided radiographic technique used to place medication in this region. Distension of the bursa with contrast was used to clearly identify the limits of the navicular bursa, to distinguish tissue in the bursa from adhesions, and to identify other injuries not clearly defined without fluid distension of the bursa (Figure 1). Initially, this technique was performed on cadaver limbs. Currently, this technique is being used in patients to improve diagnostic accuracy in cases where the presence of adhesions or the source of the lameness is not clearly defined on the initial MR study (Figure 2).

In several cases with tissue in the navicular bursa that appeared adhered to various structures, the abnormal tissue was easily displaced with distension of the bursa. Additionally, communication of tendon tears with the navicular bursa was an important finding. Following distension of the bursa, fluid in the navicular bursa could be identified entering the tendon tears. This finding indicates a surgeon could access the tendon lesion through the navicular bursa for surgical debridement. In addition, certain tendon lesions had

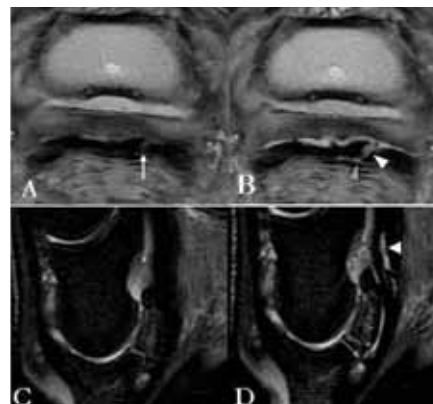


Figure 2: Transverse Proton Density (A,B) and sagittal STIR (C,D) images of a foot. A lesion is present in the lateral lobe of the DDFT prior to distension of the bursa (arrow on A). Following distension of the navicular bursa (B), it is evident that this is a tear that communicates with the navicular bursa (white arrowhead on B). Fluid has entered the tear defining the margins, and fluid can be identified extending through the tear indicating the tear is complete (grey arrowhead). Communication of the tendon tear with the navicular bursa reveals potential surgical access with bursoscopy. Prior to distension, there is no abnormal signal intensity within the DDFT on STIR images (C,D). Following distension, there is fluid signal intensity present within the DDFT, indicating fiber disruption (white arrowhead on D). Adhesions can be identified between the DDFT and DSIL (grey arrow on D).

more extensive fiber disruption than was identified on the initial MR study. The fluid entered the tendon tears demonstrating that they were longer or wider than was initially seen. Additional findings that were not previously identified until the bursa was distended included small flexor surface erosions that were obscured due to the close proximity of the dorsal margin of the DDFT. Furthermore, a greater number of cases than expected with DDFT lesions did not have adhesions to the navicular bursa, which improves the prognosis.

In addition to being used as a diagnostic aid, treatment can be administered at the time of bursal distension. Injection of the navicular bursa with corticosteroids, sodium hyaluronate, and amikacin has been described as treatment for horses

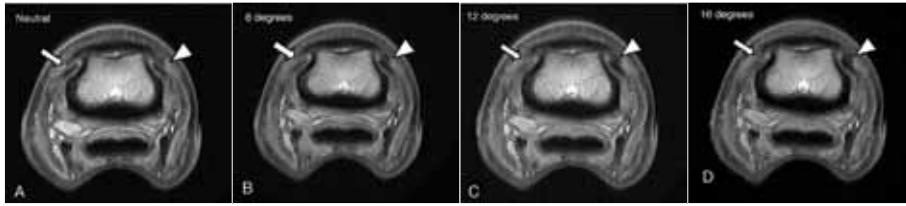


Figure 3 (A-D): Transverse of a limb placed straight in the magnet (A) and then angled 8 (B), 12 (C) and 16 (D) degrees relative to the magnet. The signal intensity in the medial collateral ligament (arrow, left side of image) gradually increases with increasing angle. The area of low signal intensity in the lateral collateral ligament (arrowhead, right side of the image) increases in size. The change in angle places more fibers in the medial collateral ligament closer to 55 degrees increasing the magic angle effect while moving the lateral collateral ligament further away and decreasing the magic angle effect that is present with the limb in a neutral position. When the limb is placed in the magnet at an angle, the signal intensity of the collateral ligaments is asymmetric. The increased signal intensity in the medial collateral ligament could be confused with injury. However, now it can be identified as an artifact.

with chronic palmar heel pain that are unresponsive to corrective shoeing and systemic nonsteroidal anti-inflammatory medication. The incorporation of navicular bursa injection with cases undergoing MR for palmar heel pain may be beneficial.

In summary, distension of the navicular bursa can be a valuable diagnostic tool when the presence of adhesions cannot be definitively determined, or if the severity and location of adhesions needs to be verified. The initial MR images can be evaluated to determine if this technique is indicated and if the navicular bursa should be treated with the same injection. Bursal distension is not required in all palmar heel pain cases undergoing examination with MR; however, the benefits of its use in clearly delineating pathologic processes can provide a more accurate diagnosis.

Magic Angle Effect in Normal Collateral Ligaments of the Distal Interphalangeal Joint in Horses Imaged With a High-Field Magnetic Resonance Imaging System

Magnetic resonance imaging is the gold standard for imaging of musculoskeletal injury. Magnetic resonance imaging is commonly used to diagnose soft tissue injuries in the equine foot because the hoof capsule prevents a complete ultrasound examination of this region

to be performed. Soft tissue injury is diagnosed by identifying areas of abnormal signal intensity, the structure of interest is a lighter or darker shade of grey than is normally present and may be increased in size.

Magnetic resonance imaging is complicated modality. The images produced have many artifacts that result from the method in which the images are acquired, not from any malfunction of the system or operator. Understanding and identifying these artifacts are imperative for correct interpretation of the images and an accurate diagnosis. One of the artifacts that can be commonly encountered on MR images is magic angle effect. Magic angle effect causes fibers oriented at a certain angle ($55^\circ \pm 10^\circ$) to have artifactual increase in signal intensity. The fibers appear light gray instead of black. This increase in signal intensity or gray appearance can be confused with injury if not properly recognized as an artifact. Magic angle effect has been previously recognized in the distal aspect of the deep digital flexor tendon on high field MR systems. However, this effect had not been recognized in the collateral ligaments of the distal interphalangeal joint on high field MR images.

A study completed at the Gail Holmes Equine Orthopaedic Research Center demonstrated that magic angle effect

occurs in the collateral ligaments of the distal interphalangeal joint. In most studies, this effect occurs in the collateral ligaments of the distal interphalangeal joint at the level of the middle phalanx (Figure 3). If the limb is placed straight within the magnet and equidistant from the magnet housing, the effect impacts the appearance of the medial and lateral collateral ligaments equally. Often the limb is placed in the magnet at an angle, with the toe higher or lower than the rest of the limb. In these cases, this artifact affects the ligaments differently, creating asymmetry in the appearance of the ligaments. It can also make one ligament appear larger than the other. The asymmetry in the appearance of the ligaments, both in size and signal pattern, can be mistaken for injury.

This study provided a guide showing the amount of change in the appearance of the ligaments based on the angle of the limb relative to the magnet housing. The purpose of this study was to prevent this artifact in the collateral ligaments of the distal interphalangeal joint to be mistaken for injury. This study also provided insight into the fiber pattern present within these ligaments and how this fiber pattern affects their appearance on MR images. There are multiple fiber bundles within these ligaments oriented at different directions. This is in contrast to the fiber pattern present in a normal deep digital flexor tendon, which has fibers that are uniformly aligned. The variation in the fiber alignment in the collateral ligaments of the distal interphalangeal joint causes variation in the signal pattern on MR images as result of the normal anatomy. This should not be confused with injury. In general, ligaments have more complicated anatomy in comparison to tendons, and are therefore more difficult to interpret on MR studies. Insight into the anatomy of the ligaments as well as the artifacts which can affect them will facilitate proper diagnosis of injury on MR studies.

Osteoarthritis: Not Just an ‘Old-Horse Disease’

Studies show 60 percent of all equine lamenesses are related to osteoarthritis, and while it is incurable, there are treatments available and research is ongoing.

By Stacey Oke, DVM, MSc

Reprinted with permission from The Horse: Your Guide to Equine Healthcare. Visit www.TheHorse.com for more horse health information and free e-newsletters.



There is no need to start panicking about osteoarthritis (OA) the day your foal’s feet hit the ground, but its impact should be considered following every footfall thereafter.

When a horse owner says, “My horse has arthritis,” the image that often first pops into our heads is an older, wizened, slightly swaybacked, retired horse standing alone in a field slowly plodding along, while his younger counterparts gallop happily past.

“This is simply not an accurate picture of a typical horse with OA,” laughs C. Wayne McIlwraith, BVSc, PhD, FRCVS, DSc, Dr. med vet (hc), Dipl. ACVS, Barbara Cox Anthony University Chair, and Director of the Orthopaedic Research Center at Colorado State University.

In fact, the available data show that more than 60 percent of equine lameness is attributable to OA, and it is widely accepted that OA can affect any horse at any age. However, we have no firm numbers to show exactly which young horses get the disease.

Because there is no cure, the management and prevention of OA continues to be a hot topic for equine practitioners and researchers. Recently, Dr. McIlwraith presented an update on OA for his colleagues at the 11th Congress of the World Equine Veterinary Association, held in September 2009 in Guarujá, Sao Paulo, Brazil. This article communicates Dr. McIlwraith’s key points presented at WEVA and relays the most recent research on various treatment modalities to keep young horses with OA functioning as fully as possible.

OA in Younger Horses

Osteoarthritis is a disease of joints with multifactorial causes that results in the progressive degradation and destruction of articular cartilage: the very thin layer of highly specialized connective tissue lining the ends of the long bones where they join. In young horses OA is predominantly trauma-related.

“Trauma can damage joints via a number of ways, but can be categorized into two major pathways: abnormal forces on normal cartilage or normal forces on abnormal (diseased) cartilage,” explains Dr. McIlwraith.

For example, repeated cycles of athletic trauma, loss of stability or development of joint incongruities (e.g., secondary to fractures, ligament injuries, etc.), and remodeling and microfracture in the bone underlying the articular cartilage

can all negatively impact normal articular cartilage. Similarly, normal forces on cartilage damaged via synovitis and capsulitis (i.e., inflammation of the lining of the joint and the capsule overlying the joint, respectively), the normal aging processes, or conditions such as osteochondrosis (failure of the bone that underlies articular cartilage to mineralize; can lead to osteochondritis dissecans, or OCD) can equally and negatively affect the cartilage in joints.

“Regardless of the underlying cause, the result is the physical breakdown of articular cartilage culminating in a hot, swollen, painful joint and loss of function,” Dr. McIlwraith says.

The Impact of OA

Osteoarthritis continues to be an important topic in equine practice because of its far-reaching impact.

“According to the American Horse Council, the horse industry has a total impact of more than \$100 billion on the U.S. gross domestic product,” relays Dr. David Frisbie, DVM, PhD, Dipl. ACVS, a leading researcher in the field of osteoarthritis, who’s based at CSU’s Gail Holmes Equine Orthopaedic Research Center.

Osteoarthritis resulting in loss not only impacts the horse and owner, but also the more than 4 million people associated with the industry, including trainers, service providers, and associated business owners.

“Treatment costs for OA include those direct out-of-pocket expenses (i.e., treatment-related costs), plus indirect costs such as lost income due to time spent on the affected horse instead of working, lost leisure time, and increased



Horse rehabilitating in underwater treadmill.

time and expenditures managing the patient with OA,” says Dr. Frisbie. “Together, these direct and indirect costs can accrue, particularly with horses that develop OA at a very young age.”

Lifelong Treatment

Osteoarthritis is a progressive disease with no known cure. This means that once a horse develops it, OA will slowly progress for the remainder of the horse’s life. Treatment invariably will be necessary at some point during an affected horse’s life to manage pain and discomfort, control swelling, prolong the horse’s athletic function (which can include competing or simply trail riding), and maximize his lifespan. At present, a multimodal treatment approach is advocated. This includes:

- Pain management via administration of nonsteroidal anti-inflammatory drugs (NSAIDs) or corticosteroids;
- Intra-articular medications (hyaluronic acid, polysulfated glycosaminoglycans);
- Intramuscular polysulfated glycosaminoglycans;
- Weight management;
- Nonweight-bearing exercises (e.g., swimming) and physical therapy;

- Dietary modification (adding omega-3 fatty acids); and
- Oral joint health supplements including glucosamine, chondroitin sulfate, methylsulfonylmethane, avocado/soybean unsaponifiable extracts, etc.

Administration of anti-inflammatory drugs – orally, topically, intravenously, or intra-articularly – remains a mainstay in OA management. Nonsteroidal anti-inflammatory drugs, such as phenylbutazone (Bute), are likely the most well-known and accessible treatments; however, clinicians have increasingly recognized safety concerns and encouraged alternatives.

“NSAIDs that inhibit the enzyme cyclooxygenase-2 (COX-2) such as firocoxib are associated with fewer side effects than Bute, which inhibits COX-1,” says Dr. McIlwraith.

The potential negative side effects from the COX-1 inhibitors spurred the development of topical NSAIDs, including the U.S. Food and Drug Administration-approved product containing 1 percent diclofenac sodium (trade name Surpass). This product, because it is applied topically to the skin overlying one or more joints, does not

appear to have the negative side effects seen with some orally administered NSAIDs. Given the low systemic absorption of this product, clinicians expect fewer potential side effects than with orally administered NSAIDs.

“Using an experimental model of OA, the diclofenac cream had both symptom- and disease-modifying effects, meaning that it improved clinical signs of disease and slowed the progression of OA,” says Dr. Frisbie.

Injecting anti-inflammatory corticosteroids intra-articularly is also an extremely common treatment method. But Dr. McIlwraith says not any old steroid will do the trick.

“Marked beneficial effects have been noted after using betamethasone esters (trade name Celestone) and triamcinolone acetonide (trade name Vetalog), and deleterious effects have been identified when methylprednisolone acetate (trade name Depo-Medrol) is injected,” he says. “Despite widely relaying this finding, methylprednisolone acetate continues to be an all-too-commonly used steroid in horses with OA that will ultimately prove to expedite loss of articular cartilage, loss of function, and loss of the horse.”

Betamethasone and triamcinolone each can be used alone; however, it is common practice to use a combination of steroid and hyaluronic acid. Dr. Frisbie and colleagues revealed in studies that the product used (Hyvisc), injected 14, 21, and 28 days after surgically inducing OA, had disease-modifying effects on OA.

“Similar results were obtained with intra-articular polysulfated glycosaminoglycans, supporting the use of this product as well in horses with OA,” notes Dr. Frisbie.

Going the Extra Mile

In addition to the above-mentioned approaches, several emerging therapies for equine osteoarthritis are either newly available or on the horizon. The

continued on Page 10

available data regarding these techniques were reviewed by Dr. McIlwraith during his presentation at WEVA and are summarized here.

Autologous conditioned serum (trade name IRAP™, which stands for interleukin-1 receptor antagonist protein): This commercially available tool involves using the horse's own blood to generate "conditioned serum" after incubating the blood sample with specially designed beads. This serum is enriched with growth factors and anti-inflammatory mediators, such as interleukin-1 receptor antagonist (IL-1ra). The clinician then injects the conditioned serum intra-articularly. Investigators performing studies at CSU demonstrated both symptom- and disease-modifying effects. IRAP™ is also used for soft tissue injuries, but when it comes to joints, it is primarily indicated post-surgically (e.g., after removal of articular chip fractures) or in horses

with OA that are no longer responsive to intra-articular injections of hyaluronic acid and Vetalog.

Platelet-rich plasma: This is a fraction of whole blood that contains a concentrated source of platelets, which are microscopic storage facilities for a variety of growth factors that facilitate healing. This treatment is also commercially available, but clinicians primarily use it in the management of soft tissue injuries and skin healing. No controlled studies evaluating PRP in OA have been conducted.

Gene therapy with IL-1ra: This agent is an inhibitor of the inflammatory mediator IL-1. Dr. Frisbie and colleagues have been working on inserting the IL-1ra gene into a virus to deliver high doses of the IL-1 inhibitor into joints with OA.

"We are hoping that this technique, referred to as gene therapy, will effectively arrest OA in the horse and will be a clinical reality in the near future," relays Dr. Frisbie.

Extracorporeal shock wave therapy: Scientists studied ESWT using an experimental model of osteoarthritis. It appears to be useful in decreasing synovial membrane and joint capsule inflammation, and it improves signs of OA in affected horses.

Physical therapy and rehabilitation: While widely recommended and utilized throughout the industry for horses with musculoskeletal injuries, little data is available supporting the presumed beneficial impact of physical therapy on OA. To remedy this, a study is currently under way at CSU using an experimental model of OA to assess the effect of underwater treadmill use on OA.

"We anticipate data to be available in the next year," says Dr. Frisbie.

Preventing OA

Since the exact pathways by which OA develops in horses remain largely ill-defined, preventing OA is challenging.

"In younger, healthy horses with repeat trauma, the focus should be placed on minimizing injury and promptly treating

causes of joint instability, such as intra-articular fractures, ligamentous tears, and incongruent joint surfaces (caused by effect of OCD)," suggests Dr. McIlwraith. "Early treatment of inflammatory conditions in the joint tissues, such as synovitis or capsulitis, can delay or possibly even prevent OA."

Prophylactic use of IM polysulfated glycosaminoglycans is widespread; but the beneficial effect of this practice remains to be demonstrated in controlled clinical trials.

"Due to the challenges associated with equine experiments, the prophylactic use of PSGAGs is not currently being evaluated," says Dr. McIlwraith. "That said, it is agreed that prophylactic intramuscular administration is not likely to be harmful."

Another potential (and possibly more economical) approach to preventing OA is the use of a glucosamine- and chondroitin sulfate-containing oral joint health supplement prior to injury, trauma, or development of OA. According to Dr. McIlwraith, unlike studies of polysulfated glycosaminoglycans in horses, research in dogs does support the use of OJHSs prophylactically. Specifically, dogs receiving a glucosamine/chondroitin sulfate combination product for 21 days prior to induction of an experimental acute synovitis had significantly less evidence of joint inflammation than the control group or dogs that were treated after the induction of the synovitis.

Dr. McIlwraith explains, "Similar studies evaluating the prophylactic use of OJHSs to prevent OA in horses have not been published, but OJHSs are widely used for this purpose throughout the equine industry."

Take-Home Message

It is important to recognize that any horse can develop OA and that each horse owner's and veterinarian's approach to treating or preventing OA will vary. Even though OA is incurable, it does not mean that OA is unmanageable.

Caution Required With Some NSAIDs

Oral nonsteroidal anti-inflammatory drugs are a mainstay in the management of osteoarthritis in horses. Of these, phenylbutazone (Bute) is one of the most popular choices.

While many horses tolerate Bute well, serious and potentially life-threatening side effects can occur, such as gastric ulcers, kidney dysfunction, and right dorsal colitis (diarrhea). According to experts, there is extreme variability in how horses tolerate Bute administration (even when administered at recommended doses), and some horses cannot tolerate even short-term administration of the drug. Firocoxib, a COX-2 inhibitor, is reportedly a safer NSAID than Bute.

Another option for managing OA is the use of a topical NSAID (1 percent diclofenac sodium, trade name Surpass), which is only minimally absorbed systemically, but can ameliorate the clinical signs of osteoarthritis.

Searching for Solutions

An abundance of equine orthopedic research is under way at Colorado State.

By Marcia King

Reprinted with permission from *The Horse: Your Guide to Equine Healthcare*. Visit www.TheHorse.com for more horse health information and free e-newsletters.

“I wanted to answer questions that hadn’t been answered.” So says Dr. Wayne McIlwraith, BVSc, PhD, FRCVS, DSc, Dr. med vet (hc), Dipl. ACVS, about his arrival some 30 years ago as an assistant professor and equine surgeon at Colorado State University’s Department of Clinical Sciences in the College of Veterinary Medicine and Biomedical Sciences. Those questions concerned how to better diagnose and treat musculoskeletal problems, particularly joint (articular) injuries and osteoarthritis: “Sixty percent of horses retire because of osteoarthritis – loss of articular cartilage and degradation of articular cartilage. It’s a huge, frustrating disease.”

The quest for those answers soon led the young New Zealander to form the Orthopaedic Research Center at CSU in the mid-1980s. “I came to CSU in 1979 having just finished my PhD at Purdue and started doing relatively small research projects with surgical residents,” recalls Dr. McIlwraith. “I had supervised three PhD students when Dr. Rick Howard started a PhD with me in 1993 and, working in Dr. Jenny Nyborg’s lab (a very good molecular biology researcher), Rick cloned the gene sequences for interleukin-1 and interleukin1 receptor antagonist that set us on an upgraded pathway. Drs. Chris Kawcak and Dave Frisbie, during their residencies, set up a small laboratory in the Vet Teaching Hospital, where we started doing more sophisticated analyses, and this was when the ORC started to take off. I wanted to get to the next level of research, and this was aided by a foundation providing me with four years’ salary for Drs. Kawcak



and Frisbie to stay with us as assistant professors within the research program. “We had a number of missions,” says Dr. McIlwraith. “To get better methods to repair articular cartilage defects, to develop better methods of early diagnoses prior to earlier treatment and to treat these problems more effectively, and to see if we could predict catastrophic fracture. We’d gone through a phase where arthroscopy enabled us to treat a lot of things successfully, but not everything successfully; there were limitations, and if there was too much osteoarthritis or cartilage loss, the horse wasn’t going to come back.”

Since that beginning, the ORC has evolved into one of the premier orthopedic research institutions in the world, with ambitious research projects, cutting-edge facilities, and innovative treatments offered to client-owned horses. Having expanded from a three-person research program, the ORC now consists of 14 faculty members and research associates, approximately 15 collaborators from other CSU departments, and a large number of

graduate, undergraduate, and veterinary students.

In addition, ORC researchers collaborate with 20 affiliate faculty and researchers from other U.S. colleges and abroad.

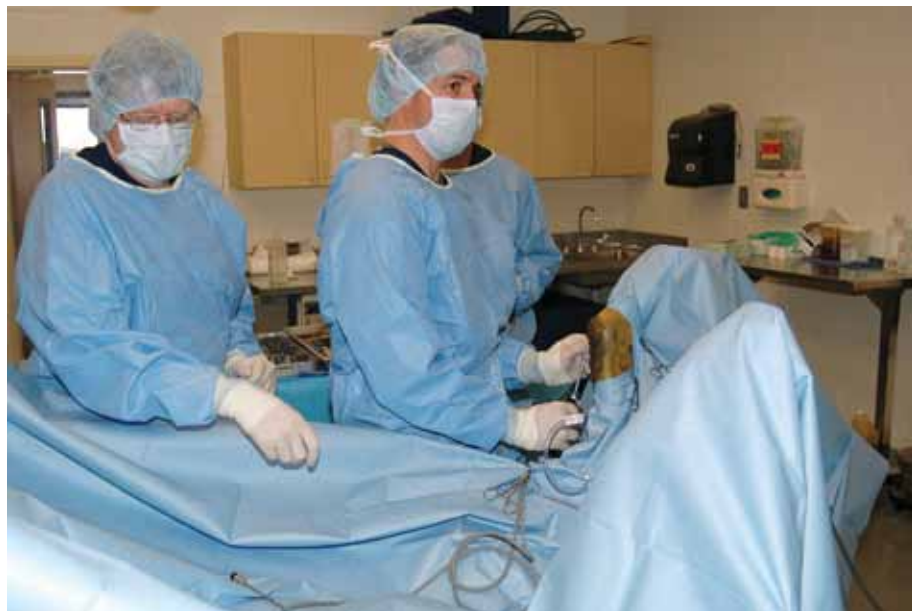Getting Results

At the ORC, researchers have developed and advanced numerous diagnostic, preventive, and treatment options for musculoskeletal problems for both horses and humans. (The horse is an excellent model for osteoarthritis and cartilage repair in people, as tissue changes that occur in the horse mimic what happens in humans.)

“We validated many of the common treatments that are used for joint disease,” Dr. McIlwraith states. “These include various intra-articular corticosteroids, hyaluronan, and PSGAG (polysulfated glycosaminoglycan, known as Adequan), providing scientific proof of what these treatments do and what their level of effectiveness is, as well as newer biological therapies such as gene therapy and autologous conditioned serum (known as IRAP™, an acronym for interleukin1 receptor antagonist protein). We’ve also done a lot of work in the better methods of healing articular cartilage. We were the first (in work led by Dr. Frisbie, DVM, PhD, Dipl. ACVS) to do gene therapy against osteoarthritis. We’re among those who are leading the way in terms of stem cell research for horses, and we’re using stem cells clinically.”

Many of the arthroscopic surgical techniques currently used for treating human and equine joint problems were developed at the ORC, techniques that have allowed for continued athletic performance.

continued on Page 12



Drs. Wayne McIlwraith (left) and Chris Kawcak perform surgery at Colorado State University.

Measuring Pain

The ORC also introduced the use of pressure algometry (a compressive-force gauge that measures the force in pounds/kilograms required to produce pain) to measure pain thresholds in horses with back pain. This important breakthrough provides a more objective assessment of back pain and also offers the ability to quantify the therapeutic effects of various pharmaceutical or nontraditional methods, such as chiropractic, physical therapy, or acupuncture.

Explains Kevin K. Haussler, DVM, DC, PhD, an assistant professor who has investigated the use of pressure algometry in horses, “Most of our current methods of pain assessment in horses are based on behavioral responses or scales or reactions to digital palpation, which are often very subjective. Pressure algometry demonstrated that some horses have a lot more widespread pain (sensitization) than previously appreciated: Some horses with presumed sacroiliac joint pain have had lowered pain thresholds all the way up to their withers, which I would have never been able to identify without the use of an objective pain measurement tool.

“Pressure algometry has also shown that phenylbutazone (Bute) is not very effective for reducing pain thresholds in normal ridden horses, compared to massage therapy or chiropractic care,” notes Dr. Haussler. (See TheHorse.com/11573 for his review of studies using this device.)

Still Searching

Among the dozens of projects under way, Dr. McIlwraith cites biomarker work for preventing catastrophic injury, stem cell therapy, inhibiting osteoarthritis with gene therapy, continued work with cartilage repair, and analysis of racetrack surfaces as among the critical investigations.

“The one I have a real passion for at the moment are factors to reduce catastrophic injury, (in) particular the biomarker work,” he says. Serum biomarkers could detect early articular cartilage and subchondral bone damage consistent with joint disease, as well as pre-fracture disease. “It’s difficult work, we’re not there yet, but I think it’s the best potential answer to identifying a horse at risk before he fractures,” he says.

In regard to catastrophic injury, another project in the works is designing

computer models that help identify racehorses predisposed to catastrophic injury of the fetlock joint. Explains Dr. Kawcak, DVM, PhD, Dipl. ACVS, now an associate professor at CSU and a senior scientist in the ORC, “We just completed a study in which we discovered that horses that have fractured had a significant change in the shape of their fetlock joints compared to those that did not. We can detect this with computed tomography and are currently comparing this to radiographs. We think this may develop as a foal, and we are currently evaluating the effects of abnormal conformation on joint shape. The hope is that we can better monitor and manipulate the limbs in foals in order to maximize safety during training and racing.”

The goal of the gene therapy research currently being done by Laurie R. Goodrich, DVM, PhD, Dipl. ACVS, an Assistant Professor in Equine Surgery and Lameness, is to genetically reprogram cells in the joint to overproduce a protein that halts and reverses joint inflammation. This might be achieved by using and delivering to the joint a specific viral vector that’s encoded with a DNA sequence that blocks the inflammatory process.

“This work has come along by leaps and bounds in the lab testing part,” reports Dr. Goodrich. “We hope to test it and apply it to horses in the next 12 to 18 months. This would be the most biological way to stop inflammation and to promote cartilage and joint healing in an arthritic joint.”

Other projects at the ORC include:

- Validating manual therapies, such as chiropractic treatment, to identify specific mechanisms of action and to assess their efficacy in reducing pain and muscle hypertonicity (increased rigidity, tension, and spasticity) and improving spinal mobility and performance in equine athletes.
- Validating rehabilitation techniques (i.e., underwater treadmill rehabilitation and hyperbaric therapy) to identify which specific

disease conditions or injuries certain modalities are effective in managing, and to develop optimal treatment protocols for select disease processes.

- Continuing development of novel imaging techniques, including ongoing validation of MRI, CT, and ultrasound.
- Continuing to evaluate new treatments, including pentosan polysulfate, oral nutraceuticals, biologic therapies, and shock wave therapy.
- Using blood samples to monitor the effects of exercise on musculoskeletal development in foals, as well as in mature athletes.
- Evaluating the use of the Dynamix shoe (a novel polyurethane shoe)

in treating navicular syndrome, and comparing the Dynamix shoe to regular egg bar shoes and “natural balance” shoes.

- Validating instrumented shoes and development of lightweight sensors (EquuSys) to monitor forces in the galloping horse.
- Assessing racetrack surface and safety (in several collaborative projects with Mick Peterson, PhD, professor of engineering at the University of Maine).

Onward

In 2001, Dr. McIlwraith became the full-time director of CSU’s orthopedic research program (now called the Gail E.

Holmes Equine Orthopaedic Research Center), and in 2009 he was made a University Distinguished Professor (CSU’s highest honor). He was bestowed the honor due to his work as a researcher, clinician, and educator, his leadership skills, and for the development of numerous programs at Colorado State, including the musculoskeletal research program.

Despite the successes and the achievements of the ORC, the quest continues for answers to familiar challenges: How to devise better diagnostics, achieve better cartilage repairs, develop better osteoarthritis treatments, and find better prevention measures.

Incidences of Radiographic Changes in Quarter Horse Yearlings Identified

In a project completed by Erin Contino (MS student) working with Drs. Richard Park and Wayne McIlwraith, the prevalence of radiographic changes in yearlings and 2-year-old Quarter horses intended for cutting was done. This project was done in collaboration with Western Bloodstock and the repository at the National Cutting Horse Association Futurity sale as well as a private farm.

Radiographs of the carpi (knees), hocks, fetlocks, and stifles were evaluated and radiographic changes characterized by type and location. Frequency of lesions was calculated and comparisons were made between the two age groups. Of 458 included horses, 408 (89.1 percent) had radiographic changes, including tarsi in 304, stifles in 202, hind fetlocks in 155, four fetlocks in 131, and carpi in 27 horses respectively.

Changes in the medial femoral condyle included flattening (21.6 percent), superficial defects (8.1 percent), defects through the subchondral bone plate (6.6 percent), and cystic lesions (5.1 percent). Osteophytes were the most common findings in the tarsal joints affecting 45.9



percent of horses. Lysis in the distal tarsal bones was the second most frequent finding affecting 17.3 percent of horses.

A second study is approaching completion looking at the effect of these radiographic changes on soundness as well as earnings in subsequent cutting completion. These findings point out that radiographic changes are very

common in repository radiographs. The second study revealing their significance will be reported in our next newsletter.

This study was made possible by the generous support of the Stallion Auction by the generous donation of breedings and the purchase of such in the Stallion Auction from the cutting horse industry.

New Staff and Student

Melissa Dicamillo, BS



Melissa Dicamillo joined the Equine Orthopaedic Research Center as a surgery technician in June 2010. She had previously worked on Feed Crew from July 2008 to

May 2009. She accepted the position of an animal care technician from May 2009 to December 2010. Melissa graduated from Colorado State University with a bachelor's degree in animal science in 2008. She received her master's in integrated resource management at Colorado State University in 2009. Melissa was born and raised in Delta, Colo., before moving to Fort Collins. She loves hiking, camping, fishing, and enjoying the outdoors of Colorado.

Nate Jensrud, BS



Nate Jensrud joined the Equine Orthopaedic Research Center as a research associate in March 2010. He earned his BS in forest resources with an emphasis

in Biotechnology from the University of Georgia in Athens, Ga. Nate managed a plant pathology laboratory at UGA for several years, studying the effects of *Phytophthora ramorum*, sudden oak death, before moving to Colorado in 2008. He spent several seasons working for the federal government with the U.S. Forest Service and U.S. Geological Survey before coming to the EORC. In his free time, Nate enjoys biking, skiing, and getting involved in the abundance of outdoor activities that Fort Collins has to offer. He is excited to be a part of the Colorado State University EORC team and looks forward to this new career in equine orthopaedics.

Lacy Kamm, DVM



Lacy Kamm, originally from Toledo, Ohio, graduated from the University of Michigan with a BS in cellular and molecular biology and a minor in Spanish. She then

attended vet school at Colorado State University. Afterward, she completed an internship at Rood & Riddle Equine Hospital in 2008 and spent a year as a graduate student at Cornell University, where she studied cytokine expression and inhibition. Lacy returned to CSU as a resident at the Veterinary Teaching Hospital in 2009 and joined the ORC as a master's student under the direction of Drs. Laurie Goodrich and David Frisbie. Lacy, under the direction of Dr. Goodrich, is working on a project where she will explain the anatomy of the pastern joint in order to perform arthroscopy on the joint. Lacy is also working on a project with Dr. Frisbie comparing protein biomarkers in osteoarthritic joints with microarray and PCR results. The goal of this study is to determine if gene expression in peripheral white blood cells can diagnose osteoarthritis in the horse. In her spare time, Lacy enjoys playing tennis, riding horses, playing and listening to music, and traveling.

Nikki Phillips, BS



Nikki Phillips graduated from Tulane University in New Orleans in 1997 and worked at the Tulane National Primate Center until 2001, when she moved with her

family and started working at Colorado State University. Nikki joined the Equine

Orthopaedic Research Center as a research associate in the laboratory in January 2009. Nikki, in her limited spare time, enjoys gardening.

Ashley Radecky, BS



Ashley Radecky joined the Equine Orthopaedic Research Center as an accountant in March 2010. She is originally from Alpine, Wyo., and graduated from

the University of Wyoming with a BS in business administration and accounting. Ashley is pursuing her master's in accounting at Colorado State University. In her free time, Ashley is an avid fly fisher and races dirt bikes on the Rocky Mountain Enduro Circuit. She enjoys many activities that give her a chance to spend time with her husband in the mountains.

Jennifer Suddreth, BS



Jennifer Suddreth, originally from Altamont, Utah, graduated from Colorado State University in 2009 with a bachelor's degree in equine science and agricultural

business. Jen started at the Equine Orthopaedic Research Center on Feed Crew and then returned after graduation to work as an animal care technician. Jen joined the EORC full time as barn manager and volunteer coordinator in June 2010. In her spare time, she enjoys working with her horse, snowboarding, and anything that gives her a chance to be outdoors.

2009 Equine Orthopaedic Research Center Supporters

William E. Morgan Society –
\$100,000 - \$999,999

Herbert A. Allen
Steadman Philippon Research
Institute
Mark Dedomenico (Pro Sports Club)

President's Society –
\$25,000 - \$99,999

EquuSys Inc.
Jaynn Emery

1870 Club –
\$1,870 - \$24,999

Wayne McIlwraith and Nancy
Goodman McIlwraith
Rood & Riddle Foundation – Larry
Bramlage
Rocky Mountain LAE
Walton Family Foundation (Alice
Walton)
ArthroDynamic Technologies Inc.
American Quarter Horse
Oak Tree Racing Association
Community Foundation of Greater
Memphis – Lee and Melanie Taylor

Cornerstone Club –
\$1,000 - \$1,869

Kim Ellis
Dr. James P. Morehead
Robert K. Shideler, DVM
Gail W. Trotter, DVM
Lezlie Rehagen
Mill Creek Veterinary (James
Latham)
Dr. James P. and Amy J. Foley
David K. and Linda McKelvie
Michael R. Ochsner
Cindy Guagenti

Advisory Board 2010

Gail E. Holmes

Quarter Horse Owner and
Breeder

John Andreini

Racing Quarter Horse Owner and
Breeder, J & L Ranch

Rick Arthur, DVM

Racetrack Veterinarian,
California; Past-president,
American Association of Equine
Practitioners

Larry Bramlage, DVM

Specialist Equine Surgeon,
Rood & Riddle Equine Hospital

Lindy Burch

Hall of Fame/Cutting Horse
Trainer and Breeder, Oxbow
Ranch

Mark Dedomenico, MD

Thoroughbred Owner and
Breeder

Ron Ellis

Thoroughbred Racehorse Trainer

John Halley, MVB (DVM)

Veterinarian for Coolmore and
Ballydoyle, Ireland

Bobby Lewis, DVM

Elgin Veterinary Hospital;
President-elect, American
Association of Equine
Practitioners

Richard Mandella

Racing Thoroughbred Trainer;
Racing Hall of Fame

Dr. Wayne McIlwraith, BVSc (DVM), PhD

Director Orthopaedic Research
Center, Colorado State University

Maria Niarchos-Gouazé

Thoroughbred Owner, Europe

Dan Rosenberg

Rosenberg Thoroughbred
Consulting

Barry Simon, DVM

Thorn Bioscience, LLC

Melanie (Smith) Taylor

Olympic Gold Medalist Show
Jumping

Martin Wygod

Thoroughbred Owner, California

Current Research Sponsors

Grayson-Jockey Club Research
Foundation

IDEXX Pharmaceuticals Inc.

Zimmer OrthoBiologics

Pfizer Inc. – Animal Health

Isto Technologies

Vet-Stem Inc.

MBST Holdings

CEVA Sante Animale

Luitpold

Arthrex Biosystems

National Institutes of Health

Orthobiologics

Autologous Conditioned Serum in the Treatment of Equine Osteoarthritis: Protein and Gene Expression of Two Commercial Systems



Dr. David Frisbie and ORC barn manager Jen Suddreth.

Previous work at the Orthopaedic Research Center had demonstrated that autologous conditioned serum also known as IRAP™ dramatically reduced symptoms of osteoarthritis.

The inflammation-promoting protein interleukin-1 β (IL-1 β) plays a major role in the progression of OA and interleukin-1 receptor antagonist (IL-1ra) blocks this inflammatory cascade. IL-1ra is a critical component of IRAP™. More recently, a second system called IRAP II™ has become available, and research at the ORC, led by Drs. David Frisbie and Wayne McIlwraith and funded by Arthrex, has compared the protein and gene expression of the two commercial systems.

We found that the IRAP™ and IRAP II™ systems increased levels of IL-1ra over serum by 93-fold and 119-fold respectively compared to serum. In comparing IRAP II™ to IRAP™, IRAP II™ increased the concentration of IL-1ra more than IRAP™, but of more importance, IRAP II™ produced two and one-half times the ratio of IL-1ra/IL-1 β compared to IRAP™. This ratio is the critical determinant of the ability to inhibit IL-1. In addition, both products showed significant increases in TGF β and IGF1.

In summary, the study showed highly elevated levels of proteins that have been beneficial in the treatment of OA with the most recent system showing superiority over the older system.

YES! I/We want to support the work of the Orthopaedic Research Center at Colorado State University.

Enclosed is my/our gift of:

\$50 \$100 \$250 \$500 \$1,870 Other \$ _____

Please apply this gift to:

ORC Greatest Need #42113

Other _____
(please write in fund)

Name _____

This gift is from: me my spouse and me my partner and me.

Spouse's/Partner's Full Name _____

Address, City, State, ZIP _____

Home Phone # (_____) _____

E-mail _____

Home Work

This gift in honor/memory of _____
human/animal (circle which).

Please send notification of my gift to the following:

Name _____

Address _____

City, State, ZIP _____

Three ways to make your contribution:

Enclosed is a check payable to the CSU Foundation.

Charge this gift to my/our:

VISA MasterCard American Express

Card Number _____

Expires ____/____ (mm/yyyy) Card Security Code _____

Name on Card _____

Signature _____

Give online at www.advancing.colostate.edu/ORC.

Please send me information about including CVMBs in my will.

Please return this form with your gift to: Colorado State University Foundation, P.O. Box 1870, Fort Collins, CO 80522-1870.

If you have questions or need additional information, call Paula Vanderlinden, Equine Orthopaedic Research Center, at (970) 297-4165 or e-mail paula.vanderlinden@colostate.edu.

The Campaign for Colorado State University

42113/V1112